

Orthodontic Perspectives

Clinical information for the orthodontic professional

..... A 3M Unitek Publication

The MBT™ System in Practice



Dr. Hugo Trevisi



Dr. Julio Vigorito



Dr. Gladys Dominguez-Rodriguez



Dr. André Tortamanto



Dr. John Scholey



Dr. Colin Melrose



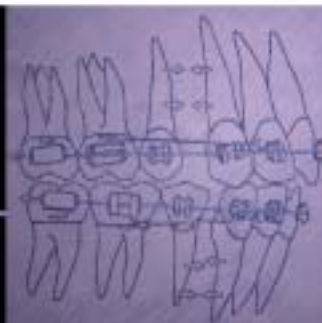Dr. Stephen Chadwick



Dr. Hideyuki Iyano



Mr. Chester Wang



Contents

Message from the President
Waldemar B. Sz wajkowski

*Space Closure Biomechanics
Applied Using The
MBT™ System Technique*
Hugo Trevisi, D.D.S. – 3

*Anchorage Control During The
Leveling Phase In Extraction
And Non-Extraction Cases
Using MBT™ System Technique*
Julio Wilson Vigorito, D.D.S., M.S.,
PhD, Gladys Cristina Dominguez-
Rodriguez, D.D.S, M.S., PhD and
André Tortamanto, D.D.S, M.S. – 8

*The MBT™ System And The
Twin Block Appliance:
The Perfect Combination?*
Dr. John Scholey, Dr. Colin Melrose
and Dr. Stephen Chadwick.
Countess of Chester Hospital,
England – 12

*Orthodontic Treatment Using The
Dental VTO And MBT™ System*
Dr. Hideyuki Iyano – 18

*The Art of Dolphin Imaging's
Arnett/McLaughlin Interactive
Treatment Analysis –
Part II. The McLaughlin
Dental VTO™*
Chester Wang – 23

Continuing Education – 27

Orthodontic Perspectives is published periodically by 3M Unitek to provide information to orthodontic practitioners about 3M Unitek products. 3M Unitek welcomes article submissions or article ideas. Article submissions should be sent to Editor, Orthodontic Perspectives, 3M Unitek, 2724 South Peck Road, Monrovia, CA 91016-5097 or call. In the United States and Puerto Rico, call 800-852-1990 ext. 4399. In Canada call 800-443-1661 and ask for extension 4399. Or, call (626) 574-4399. Copyright ©2003 3M Unitek. All rights reserved. No part of this publication may be reproduced without the consent of 3M Unitek.

McLaughlin Dental VTO is a trademark of Dr. Richard McLaughlin. Arnett STCA is a trademark of Dr. G. William Arnett. Unless noted, all other trademarks are owned by 3M.

Visit our web site at
www.3MUnitek.com

• Message from the President

by Waldemar B. Sz wajkowski



The orthodontic community always seems to be energized by true innovation. We are pleased to say that the universal response to the MBT™ Versatile+ Appliance System places it in this exceptional category.

Combining the experience and insights of Dr. Richard McLaughlin, Dr. John Bennett and Dr. Hugo Trevisi, and supported by extensive clinical results-based data, the MBT System brings together leading-edge treatment philosophy, comprehensive methodology and advanced appliance designs that, we believe, are unduplicated in the industry.

More than just an enhanced prescription, the multi-faceted MBT System has quickly been accepted as steps-ahead and broader in scope than most other solutions. While structured in format, its versatility anticipates and accommodates variances in treatment requirements. It is also supported by three major textbooks, worldwide users groups, training seminars, and most recently, new computer-based software to assist with analysis and treatment planning.

The MBT System is also a dynamic system: responding to changes, yes, but also leading the way by focusing on continuing system improvement. As a result, in just six years since its introduction, use of the MBT System has spread to thousands of orthodontists throughout the world.

This issue of *Orthodontic Perspectives* features articles from industry professionals using the MBT System in a variety of clinical situations. In the following foreword, Dr. Fredrik Bergstrand, 3M Unitek Professional Services Manager and publication Technical Editor, sets the stage for the information they provide. ■

The MBT™ System in Practice: An Overview

by Dr. Fredrik Bergstrand, 3M Unitek Professional Services Manager and Technical Editor



As Technical Editor, I wish to welcome you to the latest issue of the *Orthodontic Perspectives*. This issue is focused on the MBT System and will reflect on the versatility of the MBT prescription as well as emphasize the globalization of the MBT treatment philosophy. You will find contributions from the U.K., Japan, Brazil and USA, representing the continents of Europe, Asia and North & South America.

We have seen an increase of activities by local MBT System User Groups and in courses all over the world. This includes Australia, where during a recent trip, I had the honor of attending the inauguration of the Brisbane MBT System User Group as well as attending one of the Sydney MBT System User Group meetings.

In our first article, Dr. Hugo Trevisi (one of the MBT System founders) refocuses on the core features of MBT System treatment mechanics and elaborates on the relationship between tip, anchorage and force levels in sliding mechanics. Dr. Trevisi clearly documents three retraction systems, emphasizing the versatility of MBT system treatment mechanics. It is also food for thought to reflect on the use of AlastiK™ Ligatures versus stainless steel ligatures in these situations, considering the lowest possible resistance to sliding. In addition, Dr. Trevisi also highlights the latest innovations of the bracket system, describing the mini bicuspid tube and single molar tubes.

• Space Closure Biomechanics Applied Using The MBT™ System Technique

by Hugo Trevisi, D.D.S.



Dr. Hugo Trevisi, São Paulo, Brazil

Dr. Hugo Trevisi received his dental degree in 1974 at Lins College of Dentistry in the state of São Paulo, Brazil. He received his orthodontic training from 1979 to 1983 at that same college. Since that time he has been involved in the full time practice of orthodontics in Presidente Prudente, Brazil. He has lectured extensively in South America, Central America and Europe and has developed his own orthodontic teaching facility in Presidente Prudente. Dr. Trevisi has 25 years of experience with the pre-adjusted appliance. He is a member of the Brazilian Society of Orthodontics and the Brazilian College of Orthodontics.

With the evolution of orthodontic techniques, the sliding biomechanics has shown to be the most effective technique applied for closing spaces in extraction cases when the pre-adjusted appliance is used.

The sliding technique consists of the sliding of the rectangular archwires in the bracket slot of premolar teeth and in the buccal tube of molar teeth, allowing the remaining spaces of the extracted teeth to be closed.

The system to be presented in this article is based on the extensive clinical experience of the three MBT™ System advocates — McLaughlin, Bennett, Trevisi — who have applied this technique over a long period of time, achieving excellent force levels and resulting in tooth movement with excellent control of the biomechanics during the space closure of the extraction sites.

It is very important to emphasize that orthodontic appliances that produce tip overcorrection for anterior teeth (upper tipping using Andrews, Sabata and Watanabe figures) have caused single movement or group movement of teeth without the control of the professional during the aligning and the leveling stage of treatment (deep overbite of anterior teeth, intermediate open bite of premolar teeth, protrusion of anterior teeth). These matters require further anchorage during the space closure stage of treatment.

Because the MBT appliance system has less tipping for anterior, upper and lower teeth, the aligning and the leveling biomechanics are much more effective, as they avoid these problems. Furthermore, the sliding technique is much more sensitive when compared to appliances that have a very strong anterior tipping.

During the sliding biomechanics, the MBT system advocates recommend using a preadjusted appliance with a .022" x .028" slot, .019" x .025" rectangular steel archwires and .07mm or .08mm hooks welded or prewelded to the archwire to the mesial of the cuspid teeth (Fig. 5). In addition, .009" or .010" steel

ligatures associated with AlastiK™ Modules should be used for the retraction system.

Therefore, three retraction systems will be presented in this article. These systems have been developed from the experience of the MBT system advocates who have over 25 years of experience with the preadjusted appliance and the sliding technique.

3

Retraction System 1

It consists of applying the AlastiK module to the hook of first molar teeth and steel ligatures laced to the hooks prewelded to the rectangular archwire to the mesial of cuspid teeth. This was the first retraction system proposed by the MBT system advocates (Figs. 1 and 2).

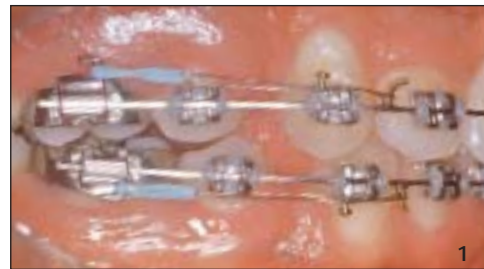


Figure 1: The AlastiK™ Module is applied to the hook of molars, and the steel ligature is laced to the prewelded hook to the archwire to the mesial of the cuspid teeth.

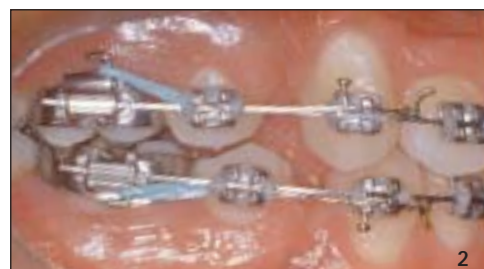

Figure 2: Resources of retraction system 1. In order to avoid the AlastiK™ Module to be in contact with the gum, it is recommended to involve the steel ligature on the AlastiK module of second premolar teeth.

Retraction System 2

It consists of lacing the steel ligature to the molars and applying the AlastiK™ Module to the hook prewelded to the archwire to the mesial of cuspid teeth. This was the second retraction system proposed by the MBT™ System advocates (Fig. 3).

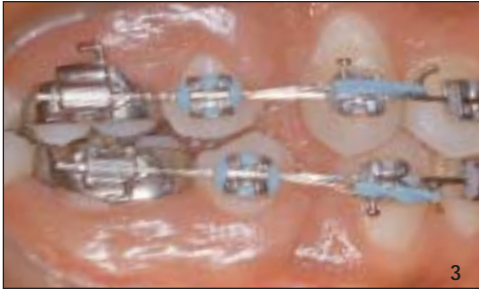


Figure 3: Firstly, the steel ligature is applied to the molars and the AlastiK™ Module placed on the hook of the archwire prewelded to the mesial of the cuspid teeth. Aiming at providing comfort to the patient, the steel ligature is placed under the AlastiK module of second premolar teeth.

Retraction system 2 allows the force to be applied over the bracket slot, enhancing the sliding mechanics and providing comfort to the patient.

④

Retraction System 3

It consists of lacing molar and premolar teeth with steel ligatures and applying the AlastiK module to the hook prewelded to the archwire to the mesial of cuspid teeth. This retraction system is similar to retraction system 2, and it has been developed to decrease friction caused by the sliding mechanics. In this system, it is not necessary to apply the AlastiK module to premolar teeth during the space closure stage of treatment (Fig. 4).

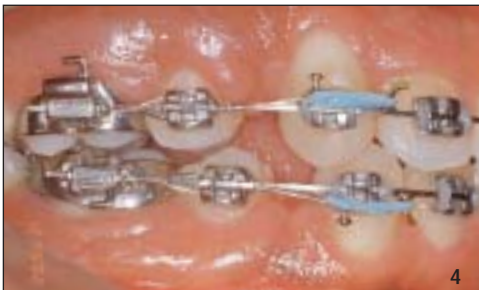

Figure 4: Retraction system 3. It consists of lacing molar and premolar teeth with steel ligatures and applying the AlastiK™ Module to the hook prewelded to the archwire to the mesial of cuspid teeth. There is no AlastiK module on second premolars.

Prewelding to the Mesial of Cuspid Teeth

Professionals should precisely establish the contact point between cuspids and the lateral incisors and use .07mm brass wire when prewelding the hooks. The fixation of the wire to the rectangular archwire is performed using a Mathieu plier. This is a very comfortable system, allowing good prewelding and not

distemperring the rectangular steel archwire (Fig. 5). **In the MBT system technique, rectangular archwires with prewelded hooks are available with three inter-cuspid distance.**




Figure 5: Brass wire prewelded to a .019" x .025" steel archwire to the mesial of cuspids.

Engagement of the Retraction Systems

Retraction System 1: Firstly, place the steel ligature to the AlastiK module (Fig. 6). Then, apply the AlastiK module to the hook of the first molar and the steel ligature to the mesial of the cuspid hook, applying the recommended activation (Fig. 7).



Figure 6: Retraction system 1. Steel ligature placed to the AlastiK™ Module.

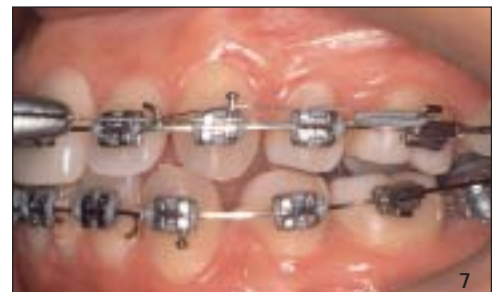

Figure 7: Engagement of retraction system 1. The steel ligature is applied to the mesial of the cuspid hook.

Retraction Systems 2 and 3: Firstly, place the steel ligature to the posterior teeth (Fig. 8). Then, apply the AlastiK module to the steel ligature, and place the AlastiK module to the mesial of the cuspid hook, applying the recommended activation (Fig. 9).

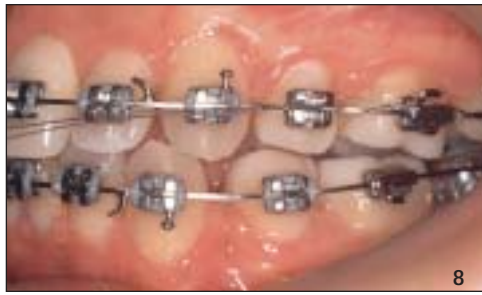

Figure 8: Engagement of retraction system 3 on posterior teeth. Engagement of the steel ligature to molar and premolar teeth.

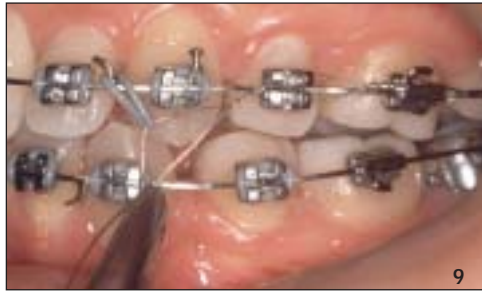

Figure 9: Engagement of retraction system 3. AlastiK™ Module applied to the mesial of the cuspid hook and activation.

Activation and Force Level

For the three systems, the MBT™ System advocates recommend activating the module to twice the size of the AlastiK™ Module (Figs. 1, 3 and 4), leaving it on the patient for twenty one days. The force level achieved in each quadrant is approximately 150g. After twenty-one days, the system can be redone or reactivated (Fig. 10).

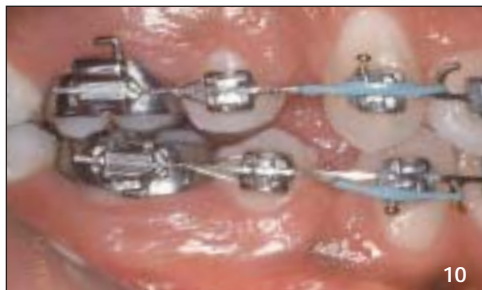

Figure 10: Retraction system 3 during the second activation after twenty one days (note that the AlastiK™ Module is twice the size of its original size).

The second activation should be twice the size of the AlastiK module or, it should be carried out until the professional feels some resistance during the activation. The system should remain set on the patient for another 21 days.

It is recommended using retraction system 3 when the force level needs to be increased, mainly when the second molar is part of the space closure biomechanics (Fig. 11).

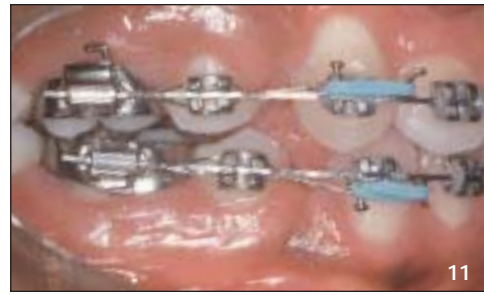


Figure 11: Retraction system 3 with two AlastiK™ Modules.

When to apply the sliding mechanics

In order to achieve perfect performance of the sliding biomechanics, the professional should follow some recommendations given by the MBT system advocates:

- Using .022" x .028" slot with .019" x .025" steel archwires.
- Leveling should be well performed. The slot plane should be well leveled, mainly in deep overbite cases.
- Using passive steel ligatures at least for 30 days in order to allow torque settlement during the initial use of .019" x .025" rectangular archwire. Then, progress to the sliding mechanics.
- Checking if there is a damaged bracket, as it causes friction during biomechanics.
- Checking if the archwire end (1mm) is at the distal of first or second molar teeth. If it does not occur, the archwire won't slide in the bracket slot.

5

MBT System Innovations:

Second premolar tubes and the MBT System technique

The use of second premolar tubes has been incorporated into the MBT system technique, and it serves to improve the resources used in orthodontic treatment. The use of these tubes brings advantages to both the professional and the patient.

Expected advantages presented by the use of second premolar tubes:

- Decreased occlusal interference of the opposing teeth, mainly in overbite and Class II cases.
- More comfort to the patient.
- Decreased bracket failure.
- Decreased friction during the sliding mechanics.

Second premolar tubes result in excellent performance during the sliding mechanics for closing remaining spaces in first premolar extraction cases and in non-extraction cases. There is no need to use AlastiK modules. Tubes are expected to decrease friction between the wire and the bracket slot and allow the spaces to be closed quickly.

Lower second premolar brackets present debonding failure because they are set in a very difficult area, in which the incidence of masticatory forces, deep overbite and Class II malocclusion are high (Figs. 12A and 12B). Then, lower second premolar tubes have been designed in order to overcome this matter. These tubes have a larger base, enhancing bonding strength, and a 1.0mm debasing. They also have a special design, allowing the biomechanics to be performed during the aligning, leveling and space closure stage of treatment.

Lower Second Molar Mini Tubes

For the great majority of patients, there has always been a difficulty in including lower second molars in the orthodontic treatment. The interocclusal space and the gingival tissue do not allow setting a band with a tube or a bonded tube of regular size on teeth. The biomechanics resources are favored when it becomes possible to include these teeth in the orthodontic treatment, mainly in deep overbite cases.

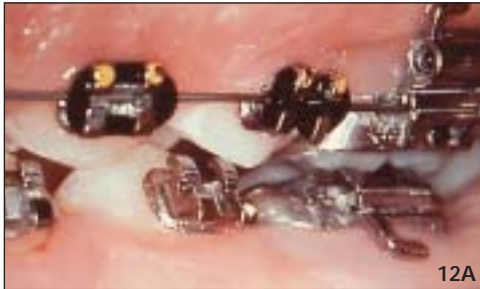

Figure 12A: Occlusal interference of upper premolar with a lower second premolar bracket.

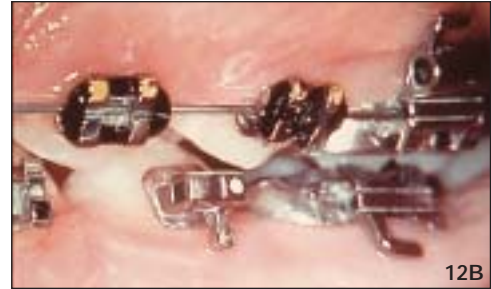

Figure 12B: Tube replacing a second premolar bracket.

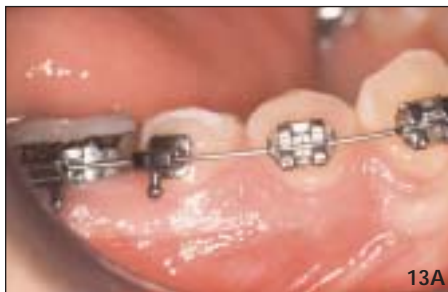

Figure 13A: Second premolar tube replacing a bracket due to bonding failure.

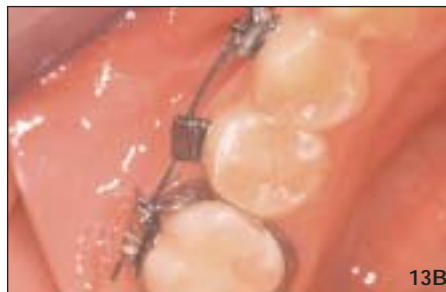

Figure 13B: Occlusal view .014" Nitinol archwire during re-leveling.

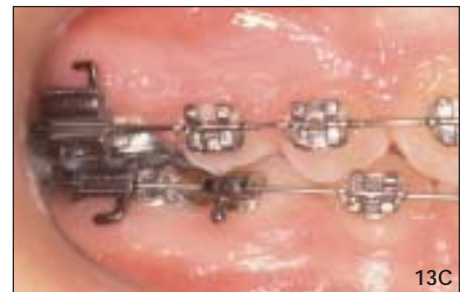

Figure 13C: Maximum intercuspation. The patient presents overbite and a slight Class II malocclusion.

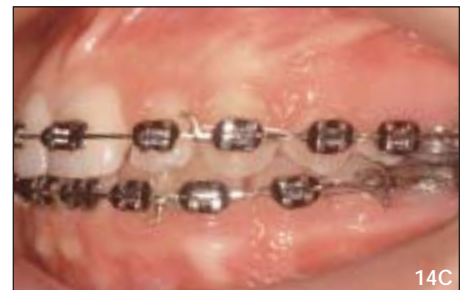
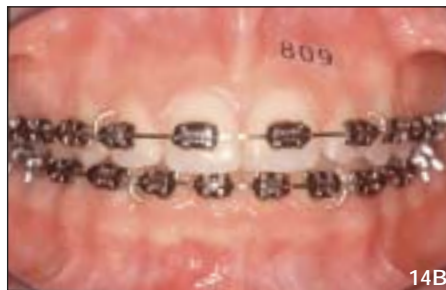
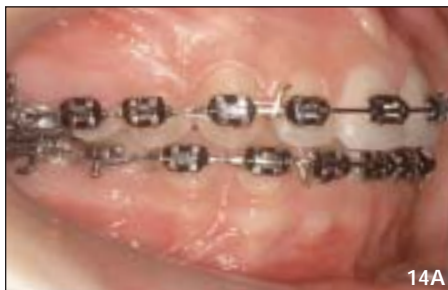Figure 14A, 14B, 14C: Space closure stage of treatment applying the sliding biomechanics and using a bonded lower second premolar tube with .019" x .025" steel archwire.

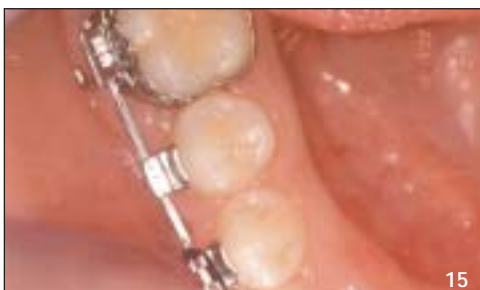

Figure 15: Occlusal view of a lower second premolar tube and .019" x .025" steel archwire during the finishing stage of space closure.

For extraction or non-extraction treatments presenting space matters, second molar impaction is a barrier to the whole course of treatment. Therefore, it is necessary to have an appliance with a design that allows the inclusion of second molars in the treatment.

Lower second molar mini tubes have been developed, aiming at providing a good bonding strength to second molar devices, placing second molars to the level of the occlusal plane of first molar teeth. Its base has been designed to be well adapted to the contour of second molar mesial cusp. And, its design has a good debase, allowing it to be set in deep overbite cases (Figs. 16A and 16B). ■

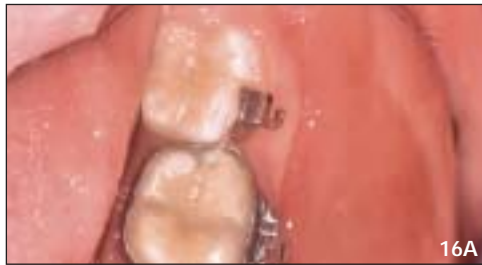

Figure 16A: Mini tubes bonded on lower second molars. In this case, it would be difficult to use a regular tube.

REFERENCES

- 1 Bennett J, McLaughlin R P 1993 *Orthodontic Treatment Mechanics and the Preadjusted Appliance*. Mosby-Wolfe, London (ISBN 0 7235 1906X)
- 2 Bennett J, McLaughlin R P 1997 *Orthodontic Management of the Dentition with the Preadjusted Appliance*. Isis Medical, Oxford (ISBN 899066 91 8). Republished in 2002 by Mosby, Edinburgh
- 3 McLaughlin R P, Bennett J, Trevisi H J 2001 *Systemized Orthodontic Treatment Mechanics*. Mosby (ISBN 072343171X)

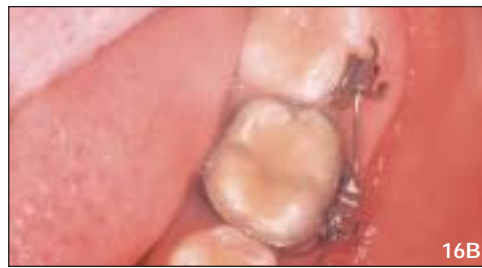

Figure 16B: Engagement of the initial aligning and leveling archwire.

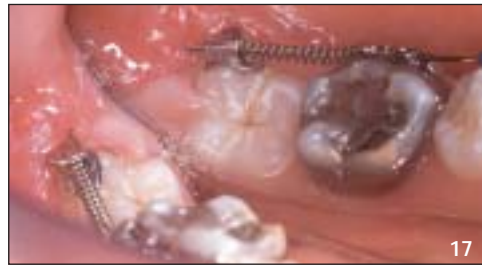

Figure 17: Lower second molar mini tube bonded to the distal on an impacted lower second molar.

- 4 Zanelato RC et al. *Mecânica de fechamento de espaço utilizando-se a técnica de deslize*. *Rev. Clínica de Ortodontia Dental Press*. v. 1, n: 5, p. 67-81, out/nov 2002
- 5 Andrew L F 1989. *Straight-Wire – the concept and the appliance*. Wells Co, LA
- 6 Ouchi, K et al. *The effects of retraction forces applied to the anterior segment on orthodontic archwire: changes in the wire deflection with the wire size*. California: Edward H. Angle Society, 2001

The MBT™ System in Practice: An Overview

Dr. Julio Vigorito, Dr. Gladys Dominguez-Rodriguez and Dr. André Tortamanto in their article address how to utilize and optimize the force play between brackets and wires using various wire materials and dimensions. There is no “one wire fits all” concept, but again the versatility of the MBT system gives us opportunities to minimize the number of wires and wire changes in order to deliver the most efficient way of moving teeth from point A to point B.

Another aspect of the versatility of the MBT system is found in the article by Dr. Stephen Chadwick, Dr. Colin Melrose and Dr. John Scholey, describing how to combine the MBT system with Twin-Block therapy in Class II correction. When challenged with the urge of using a functional appliance approach, the transition from functional to fixed appliance is critical. The authors guide us through that transition and highlight the merits of the MBT appliance system, making this an easier and more effective procedure.

The alternative approach of using the MBT prescription with fixed Class II Correctors like the Forsus™ Nitinol Flat Spring or the Forsus™ Fatigue Resistant Device has been documented in recent publications as well, emphasizing the flexibility and versatility of the prescription.

With regard to the speculation for a specific Asian prescription, I found the article & case reports from Dr. Hideyuki Iyano from Japan very interesting. Taking advantage of the option of placing

continued from page 2

the lateral bracket upside down, increasing root torque and addressing the particular needs of this case clearly illustrates the versatility of the MBT system and how it is instrumental in delivering a good end result.

Unaware of any clinical evidence, and reviewing the outcome of the two cases treated by Dr. Iyano with the MBT system, the question remains: Is there justification for a specific Asian prescription? Still, based on the awareness of Orthodontics as essentially an empirical science, I am sure there are differences of opinion regarding this matter. So I am looking forward to having our readers’ reactions and comments!

In the last article, the second of two parts, Chester Wang of Dolphin Imaging describes the McLaughlin Dental VTO™ software module, a part of the Arnett/McLaughlin Interactive Treatment Analysis. This software was developed as part of a strategic alliance between Dolphin and 3M Unitek, and is fully compatible with the MBT System. The McLaughlin Dental VTO provides a powerful and intuitive tool to assist the orthodontist to precisely treatment-plan a case.

I am sure you will find interest in reading these articles and I would like to invite you all to comment on their content by email to fbergstrand@mmm.com or by regular mail to Dr. Fredrik Bergstrand, 3M Unitek, 2724 South Peck Road, Monrovia CA 91016 USA. ■

• Anchorage Control During The Leveling Phase In Extraction And Non-Extraction Cases Using MBT™ System Technique

by Julio Wilson Vigorito, D.D.S., M.S., PhD, Gladys Cristina Dominguez-Rodriguez, D.D.S., M.S., PhD and André Tortamanto, D.D.S., M.S.



Julio Wilson Vigorito, D.D.S., M.S., PhD
Professor and Chairman of the
Department of Orthodontics,
School of Dentistry, University of
São Paulo, São Paulo, Brazil.



Gladys Cristina Dominguez-Rodriguez,
D.D.S., M.S., PhD
Assistant Professor of the Department
of Orthodontics, School of Dentistry,
University of São Paulo,
São Paulo, Brazil.



André Tortamanto, D.D.S., M.S.
Assistant Professor of the Department
of Orthodontics, School of Dentistry,
University of São Paulo,
São Paulo, Brazil.

8

Introduction

To obtain ideal goal in orthodontic treatment depends on several factors. Among others, one of the most important to be considered is the posterior tooth anchorage, principally in first premolar extraction cases. From approximately 1930 onwards, there has been concern among authors about posterior tooth anchorage control. To help avoid loss of anchorage during orthodontic treatment, Tweed suggested tip-back bends on posterior teeth.

Anchorage control can be divided into three types: namely, intraoral, extraoral or combination of both.

The most commonly used anchorage aids used currently are extraoral appliances, lip bumpers, lingual arches, transpalatal bars arches and Nance's buttons. Each of these, when indicated, can be included within the context of dental anchorage, as each is fixed directly to the teeth. The efficiency of these anchorage aids depends on the treatment plan, because tooth movement in each phase of the treatment has a direct effect on the amount of the anchorage loss. Likewise, the prescription details of the

preadjusted appliance used are also relevant. We can also clinically verify that the types of wires and their physical characteristics play an important role in posterior tooth anchorage control. In the 70's, Andrews¹ introduced the technique of the preadjusted appliances and simultaneously there occurred technological advances not only in terms of quality but also in the features of wires and accessories.

Vigorito⁸ (1996) studied tooth movement and anchorage problems during the leveling phase and states that posterior teeth undergo the consequences of the different forces and consequently move either mesially or in a buccal mesial direction. In these cases the author used an extraoral appliance in the upper arch and a lip bumper in the lower one.

McLaughlin & Bennett³ (1989) observed that after the transition from the edgewise to straightwire technique, there was an increase tendency for teeth to incline buccally, concluding that for this and for others reasons, a higher demand on anchorage control was necessary.

McLaughlin et al.⁵ (1997) presented a review on MBT™ System orthodontic planning. This technique uses a series of intra- and extraoral devices: palatal bars, lingual arches, Class II and III elastics, Nance's buttons and utility arches. The alignment and leveling phase includes:

- Use of thermo-activated NiTi arch wires,
- Use lace-back ligature to control canine retraction,
- Use of cinch back bends to control anterior movement of the incisors,
- Use of open coil to obtain space,
- Set and maintain arch form from the beginning of treatment.

Moresca & Vigorito⁶ (2002) studied the effect of two different anchorage devices, namely, headgear and Nance's button on upper teeth of Class II patients treated with the MBT System technique in which leveling was obtained by thermo-activated arches. The results showed that there was anchorage loss in the cases that used Nance's buttons and stability in those that used the headgear.

Vigorito & Moresca⁹ (2002) studied the effect of the use of the thermo-activated wires on lower molars and incisors during the leveling phase in which a lingual arch was the anchorage device.

Aim of the Study

To evaluate the possible variation of the position of lower first molars and incisors during the alignment and leveling phase in extraction and non extraction Class II/1 adolescents, treated with an MBT System preadjusted appliance where a lingual arch was used as the anchorage control device.

Material and Methods

The sample was composed of 30 Brazilian adolescents of both sexes with permanent dentition with Class II/1 malocclusion. The patients were divided into three groups as follows: Group I: 17 patients with a mean age of 15y., 5m. (ranging from 13y. 7m. to 17y. 1m.). Group II: 8 patients with a mean age of 14y., 4m. (ranging from 13y. to 15y. 9m.). Group III: 5 patients with a mean age of 14y., 2m. (ranging from 12y. 10m. to 15y. 9m.).

Groups I and II had the first bicuspid extracted during treatment, while Group III was treated without extractions.

Lateral cephalograms and plaster models were obtained from each patient before and after leveling phase. The initial radiograph was obtained after installing the anchorage system but before the extraction of the bicuspid and beginning the leveling phase. The average time between the radiographs was 12 months.

Orthodontic treatment took place in the Department of Orthodontics and Pediatric Dentistry of the University of São Paulo, by students of the Master of Science Course, under the supervision of the Authors.

The first clinical step was the installation of the fixed lingual arch as an anchorage device. Afterwards, all the brackets were bonded directly according to the position table recommended by McLaughlin & Bennett⁴ (1995). After taking the radiographs and extracting the bicuspid, the leveling phase was started on Groups I and II. On all patients, bilaterally, lace-backs of 0.25mm ligature wire was used from the hook of the molar tube to the cuspid bracket. In patients with negative model discrepancy in the anterior region, the ligatures were activated in order to obtain an initial verticalization of the cuspid. When there was no model discrepancy, the lace-backs were not activated and they were changed every three weeks.

The leveling phase was undertaken in Group I using three arches as follows:

1. 0.016" NiTi thermo-activated arch wire (OrthoForm II – 3M Unitek).
2. 0.019" x 0.025" NiTi thermo-activated arch wire (OrthoForm II – 3M Unitek).
3. 0.019" x 0.025" stainless steel arch.

In Groups II and III the arches sequence used for the leveling phase was the following:

1. 0.014" stainless steel arch.
2. 0.016" stainless steel arch.
3. 0.018" stainless steel arch.
4. 0.020" stainless steel arch.
5. 0.019" x 0.025" stainless steel arch.

In Group II the rectangular arches had passive torque in the incisors region and neutral torque in the cuspid and molar area. The leveling wires received cinch back bends distally to the second molar tube.

When crowding was observed in Group I patients, segmented arches were used and extended from the second molar to the

cuspid. In these cases the anterior teeth were included in the arch only when sufficient space was obtained and risk of undesired buccal movement avoided.

In Group III, in two out of five subjects, stripping was performed. In the other three patients, the teeth were leveled in a routine manner. Rectangular arches were placed with neutral torque in the anterior and posterior region.

Cephalometric Tracing

Cephalometric tracing was made on lateral cephalograms before and after leveling phase. The following points were marked: Gonion (Go), Menton (Me), Mesial of the crown of lower 1st molar (C6) and correspondence root apex (R6), Incisal edge (C1) and apex of the lower incisors (R1) and line S (perpendicular to Go-Me and tangent to the rearmost point of the symphysis), (Fig. 1).

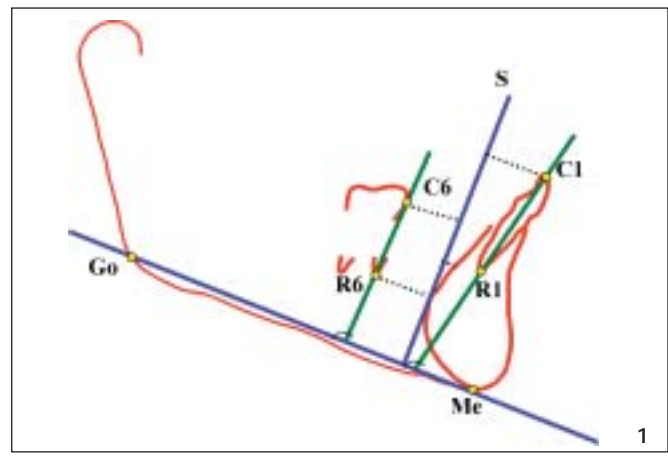


Figure 1: Cephalometric Tracing.

Results and Discussion

Biomechanical control has been of paramount importance since the beginning of orthodontic treatment. Consequently all professionals should know well all the factors that could affect the biomechanics used to correct malocclusions. So, to correct malocclusions with 1st bicuspid extraction, it is important to know that closing the extraction space will cause a loss anchorage of posterior teeth even using anchorage devices. On the other hand, in non extraction cases, during the leveling phase, the loss of anchorage could depend on treatment planning and on the choice of the different parts of the appliance such as the wire type, the anchorage system, the way arches are constructed and the prescription of the brackets and tubes. The anchorage loss could influence the management of the treatment goal dramatically. The same considerations could be made concerning the orthodontic movements in the incisor area.

Tables I, II and III show the results of the observed phases and their statistical analyses.

Table IV shows the comparison of the mean differences between beginning and end of the leveling phase of the three different groups.

TABLE I. Comparison of mean values measured before (T1) and after (T2) aligning phase in Group I

	T1		T2		difference	P
	x	SD	x	SD		
C6-S	13.88	2.7	13.35	3.06	-0.53	2.496*
R6-S	13.94	3.1	13.03	3.05	-.091	4.615***
C-R6.GoMe	90.35	7.55	89.15	8.1	-1.21	1,768
C1-S	7.91	2.25	6.24	2.31	-1.68	5.228***
R1-S	4.91	1.38	4.97	1.43	0.06	-0.293
C-R1.GoMe	97.41	4.8	93.41	4.37	-4	4.636***

*P<.05; **P<.01; ***P<.001; x, Value

TABLE II. Comparison of mean values measured before (T1) and after (T2) aligning phase in Group II

	T1		T2		difference	P
	x	SD	x	SD		
C6-S	14.21	2.7	13.78	3.19	-0.43	0.29
R6-S	15.56	1.37	15.16	2.16	-0.4	0.44
C-R6.GoMe	94.04	4.31	94.5	4.39	0.46	-0.21
C1-S	10.14	4.61	9.54	4.51	-0.6	0.26
R1-S	6.99	1.57	7.1	1.63	0.11	-0.14
C-R1.GoMe	97.94	7.91	95.84	7.73	-2.1	0.54

*P<.05; **P<.01; ***P<.001; x, Value

TABLE III. Comparison of mean values measured before (T1) and after (T2) aligning phase in Group III

	T1		T2		difference	P
	x	SD	x	SD		
C6-S	15.6	1.43	15.5	1.7	-0.10	0.101
R6-S	17.46	2.83	17.6	2.7	0.14	-0.080
C-R6.GoMe	94.7	5.07	95.4	5.49	0.70	-0.209
C1-S	7.9	1.7	8.3	1.8	0.40	0.263
R1-S	3.6	1.7	3.94	1.9	0.34	-0.141
C-R1.GoMe	100.9	1.5	100.8	1	-0.10	0.537

*P<.05; **P<.01; ***P<.001; x, Value

TABLE IV. Comparison of the differences between Groups I vs. II; II vs. III; I vs. III

	I vs. II			II vs. III			I vs. III		
	I	II	P	II	III	P	I	III	P
C6-S	-0.53	-0.44	-0.19	-0.44	-0.10	-0.608	-0.53	-0.10	-1.09
R6-S	-.091	-0.40	-1.115	-0.40	0.14	-0.731	-.091	0.14	-1.635
C-R6.GoMe	-1.21	0.46	-1.63	0.46	0.70	-0.161	-1.21	0.70	-1.329
C1-S	-1.68	-0.60	-2.496*	-0.60	0.40	-2.375*	-1.68	0.40	-4.68***
R1-S	0.06	0.11	-0.203	0.11	0.34	-0.834	0.06	0.34	-0.965
C-R1.GoMe	-4	-2,10	-1.368	-2,10	-0.10	-2431*	-4	-0.10	-0.472***

*P<.05; **P<.01; ***P<.001; x, Value

Posterior Teeth – First Lower Molars

When assessing the results of Tables I, II and III, it was noticed that the crowns of the first lower molars from the beginning of the treatment through the end of the leveling phase have mesialized significantly in Group I, whereas they have remained stable in the other two groups. Thus, a loss of anchorage of -0.53mm occurred on each side of the lower arch (variable C6-S). The same occurred with the variable R6-S. There was a loss of anchorage in Group I, while Groups II and III were stable. Therefore, when thermo-activated wires were used, the anchorage of the posterior teeth became more jeopardized, even with the use of a fixed lingual arch as anchorage aid. We believe that the reciprocal forces produced by the thermo-activated arches are very abrupt and consequently they do not allow planning the dental movement

with directional forces. In the Groups II and III the stainless steel wires tolerated a better control of the orthodontic forces owing to their biomechanical characteristics, not only on those teeth we wanted to move but also on those we wanted to make stable.

The CR6.GoMe angle did not suffer any significant change in any of the three studied groups, when the beginning and the end stages of leveling were compared, although in group I it occurred with a counter clockwise rotation of the molars and in the groups II and III, a clockwise rotation.

Comparing the three groups, I, II and III, the differences between the beginning and the end of leveling phase did not point out any statistically significant difference when the posterior teeth were considered.

Anterior Teeth – Lower Incisors

Assessing the cephalometric variable CI-S in Group I, an unusual fact can be noticed. From the beginning to the end of the leveling phase, the crowns of the lower incisors migrated, in several cases, to a lingual direction, in a very pronounced way. On average, the lingual movement of the crowns was around -1.68mm, since in the beginning the mean value was 7.91mm and in the end it was 6.24mm. The difference was statistically significant. We believe that this lingual movement can be explained by the movement of the thermo-activated NiTi arch inside the slot, which has a torque of -6 degrees. This movement may explain a higher request of anchorage on the posterior teeth, encouraging the loss. This fact was not observed in Groups II and III because the torque in the rectangular arches of Group III (stainless steel wires) besides being passive in the anterior area, did not present any lingual effect on the crowns of the incisors.

In Group III, the anterior teeth did not suffer any movement in lingual direction because the proximal contacts blocked this movement. In contrast, the crown moved in buccal direction. The root apices of the incisors remained stable in all three studied groups.

The angle between the long axis of the lower incisor and the mandibular plane (variable CR1.GoMe) showed a statistically significant difference in Group I, but none in Groups II and III.

When the three groups and the differences between the averages from the beginning and the end are compared, it is possible to notice statistically significant differences only for the CI-S and CR1.GoMe. The lower incisors suffered a much higher lingual movement of the crown in Group I compared with the ones of Groups II and III. Beside that, Group III showed significant differences of the CR1.GoMe angles when compared with those of Groups I and II, considering that in Group III the incisors suffered a buccal direction movement while in the other two groups there was a lingual direction movement.

Clinical Considerations

The obtained results in this research made us understand that the control of the anchorage of the posterior teeth of the dental arches is of great relevance to obtain the ideal goals in Orthodontics. The MBT™ Prescription is of excellent quality during the leveling stage of the dental arches, providing an outstanding placement of the teeth. The leveling and alignment of the dental arches accomplished by the three orthodontic wires, (two thermo-activated and one of stainless steel) used in Group I, can cause an undesired occlusal collapse, as a consequence of the uncontrolled performance of the thermo-activated rectangular wire. Because of its characteristics, it does not allow a suitable control of the posterior teeth anchorage, nor the control of the anterior teeth bending. The reciprocal actions of the dental movements become precarious. A tooth is “launched” against its neighbor without any control, and the actions of the rectangular wires work with a neutral torque in

slots with different torque. There are cases where the molars mesialize 2mm on each side and there are movements of anterior retraction of the incisors of 3mm. Actually, we are not rejecting the use of this sequence of arches; we are just calling the attention upon the undesired biomechanical issue. Logically in those cases that the loss of anchorage is not important, the sequence of arches used in this paper becomes excellent, since the length of the clinical session would be highly reduced.

Because the Groups II and III used sequences with round and rectangular stainless steel wires, those facts did not occur, showing a better control of the dental movement during the leveling phase.

Conclusions

Group I: The first lower molars suffered a mesial movement of the crown and of the root, and the lower incisors bent into a lingual direction, in a counter clockwise movement, during the leveling phase. The anchorage aid, Fixed Lingual Arch, was considered unsatisfactory when anchoring requests were performed during the leveling phase, probably because of the use of thermo-activated rectangular arches.

Group II: There were no statistically significant differences found between the beginning and the end of the leveling phase for the molars and lower incisors. The leveling stainless steel, round and rectangular arches, with passive torque in the anterior area, allowed a better control of the posterior anchorage and incisor position.

Group III: There were found no statistically significant differences during the leveling phase. Both, molars and incisors, kept on stable.

When the comparison was made of the differences between Groups I, II and III, it was noticed statistically significance on the position of the crown of the incisors and the tipping of long axis in relation to the mandibular plane. ■

REFERENCES

- 1 ANDREWS, L. F. Straight Wire: syllabus of philosophy and technique. 2nd Ed. Los Angeles: Wells Co., 1975, p. 137-162.
- 2 ANGLE, E. H. Classification of malocclusion. *Dento Cosmos*, v.41, n.2, p. 248-264, Feb., 1899.
- 3 McLAUGHLIN, R. P., BENNETT, J. C. The transition from standard edgewise to preadjusted appliance systems, *J. Clin. Orthod.*, v.23, n.3, p. 142-153, Mar., 1989.
- 4 McLAUGHLIN, R. P., BENNETT, J. C. Bracket placement with the preadjusted appliance. *J. Clin. Orthod.*, v.24, n.5, p. 302-311, May, 1995.
- 5 McLAUGHLIN, R. P. et al. A clinical review of the MBT orthodontic treatment program. *Orthodontic Perspectives*, v.4, n.2, p. 4-15, Fall, 1997.
- 6 MORESCA, R., VIGORITO, J.W. Estudo comparativo dos efeitos do Aparelho Extrabucal a do Botão de Nance como recursos de ancoragem durante a fase de Nivelamento utilizando-se a Técnica MBT. *Ortodontia*, vol. 35 n.1, p. 8-20, Jan/Mar. 2002.
- 7 VIGORITO, J. W. Alguns efeitos do emprego da força extra-bucal no tratamento das más oclusões dentárias. *Ortodontia*, v.13, n.2, p. 118-132, Maio/Ago., 1980.
- 8 VIGORITO, J. W. Ortodontia Clínica Preventiva. 2a. ed. São Paulo, *Artes Médicas*, 1986, p.239.
- 9 VIGORITO, J.W., MORESCA, R. Estudo cefalométrico radiográfico sobre os efeitos dos arcos termo-ativados na estabilidade dos dentes posteriores inferiores, durante a fase de nivelamento, utilizando-se o arco lingual fixo a prescrição MBT. *Ortodontia*, vol. 35, n.03, p.57 - 66, Jul/Set., 2002.

• The MBT™ System And The Twin Block Appliance: The Perfect Combination?

by Dr. John Scholey, Dr. Colin Melrose and Dr. Stephen Chadwick. Countess of Chester Hospital, England



Dr. John Scholey is a Senior Specialist Registrar in Orthodontics at the Countess of Chester Hospital and Liverpool University Dental Hospital in England. He teaches on the University of Liverpool Orthodontic training program. His research interests include publication bias and he is involved in 3 systematic reviews for the Cochrane collaboration.



Dr. Colin Melrose is a Consultant Orthodontist at the Countess of Chester Hospital and Liverpool University Dental Hospital in England. He teaches on the University of Liverpool Orthodontic training program. His clinical interests include the integration of twin blocks with MBT™ System mechanics, the management of ectopic canines, orthognathic surgery and archwire technology.



Dr. Stephen Chadwick is a Consultant Orthodontist at the Countess of Chester Hospital, Chester, England. Mr. Chadwick teaches on both the University of Liverpool and University of Manchester Orthodontic training programs. He has published a number of papers on myofunctional appliances and orthodontic education.

Introduction

The twin block appliance (TB) is now one of the most frequently used myofunctional appliances in the U.K, being the first choice myofunctional appliance for over 75% of members of the British Orthodontic Society¹ and growing in popularity across the world.

The TB was originally described by Clark in the 1980s^{2,3} and has proven to be effective, well tolerated and highly versatile, with operators undertaking a number of modifications in its design.

Although effective at reducing overjets, the TB is often used as part of a two-phase plan in which the second phase of treatment to align and detail the occlusion is carried out with fixed appliances.

In this article we will discuss, with a case example, the reported effects of the TB and how the MBT™ Prescription in the second phase of treatment facilitates an ideal outcome.

Case Selection

The original reports of the TB selected moderate Class II division 1 cases with well-aligned arches, mild to moderate Class II skeletal bases and low to average maxillary-mandibular planes angles.^{2,3} These patients still encompass the majority of the TB caseload, but modifications of the TB can be used as a means of treating a greater proportion of the Class II population. Contemporary development of the appliance is reflected by its remarkable amenability to design adaptation, allowing the TB to be used for more severe Class II cases, including crowded arches and Class II division 2 cases.^{4,5}

With continued concern regarding the compliance and risks of headgear wear,^{6,7} the TB offers a proven alternative to extra-oral traction for overjet reduction and may negate the need for extractions to facilitate bodily retraction of the upper labial segment in well aligned cases.

How does the twin block work?

There have been a number of high profile trials and review articles looking at the effects of various functional appliances. It appears that there are consistent findings that approximately 30% of the Class II correction results from a variety of skeletal effects and 70% from dentoalveolar effects⁸⁻¹⁰. These effects have also recently been reported with use of the TB.¹¹

There is also a substantial amount of evidence to show that the TB is effective at reducing overjets^{3,12-17}. As with other functional appliances, overjet reduction by the TB is brought about by a combination of skeletal and dentoalveolar effects; a summary of these reported effects are included in Table 1.

Skeletal effects of the twin block

The reported effects on the ANB value are for the most part consistent at around 2 to 3 degrees.¹²⁻¹⁶ Much of this reduction seems to be the result of a more forward positioned B point with changes in SNB of the same magnitude or half a degree below that of the reduced ANB. Restraint of maxillary growth has been described but is likely to be of far less importance unless headgear is added early to the TB.¹⁷

Many different researchers have looked at whether there is a true gain in mandibular length from TB use. Although the exact methods of taking linear mandibular length measurements vary between researchers, common findings are net increases of 2-4mm^{12-15, 17} in absolute length with greatest increases in ramal height.

Researchers	Study Details/Appliance Design	Reduction ANB (Degrees)	Increase SNB (Degrees)	Retroclination Upper Incisors (Degrees)	Proclination Lower Incisors (Degrees)	Increase In Mandibular Length	Effect On Face Height
Clark ³	Retrospective 70 consecutive cases compared to control data/ Original Clark design	Yes but values not given		Yes but values not given	Yes but values not given	Yes but values not given	Reported an increase but values not given
Lund and Sandler ¹²	Prospective clinical trial, treat n=36 untreated control 27/ Upper labial bow	2	1.9	10	7.9	Net increase Ar -Po of 2.4mm	Increase 1.5% in LFH
Mills and McCulloch ¹³	28 consecutive treated cases 28 controls from Burlington growth study/ Lower acrylic labial bow and no upper bow	2.8	1.9	2.5	5.2	Net increase Cd-Gn of 4.2mm	Net increase of 3.8mm total face height
Illing, Morris and Lee ¹⁴	Prospective RCT comparing TB bionator and Bass appliances vs control group 47 treat patients/ Adams clasps buccal segments and ball end clasps labially	2.3	0.8	9.1	2	Net increase Cd-Gn 2.4mm	Net increase of 3.7 mm total face height
Trenmouth ¹⁵	Retrospective 30 consecutive cases controls from local normative data/ Southend clasp on lower incisors	2.6	2	14	1.3	Net increase Ar -Po of 2.7mm	Not assessed
Harradine and Gale ¹⁶	Retrospective 60 cases/ 30 with upper labial bow and 30 with upper torquing spurs	1.64 and 2.9 respectively	1.2 and 2 respectively	14.1 and 6.9 respectively	4.6 and 4.7 respectively	Not given	Not given
Parkin et al ¹⁷	Used cases from the previous study (Lund and Sandler ¹⁰) and compared to new design/ High pull HG and torquing springs 27 Patients in the new group	3.8	2.4	6.9	6.2	Net Increase Ar-Po of 4.7mm	No effect (control by headgear)

Table 1: Summary of the reported effects of the twin block appliance.

There is a tendency for small net increases to the lower face height of 3-4mm which may be detrimental in high angle cases. However, this effect has been shown to be controlled by addition of high-pull headgear to the appliance.¹⁷

There have also been suggestions that there may be favorable changes to the direction of growth of the condyle coupled with a more anterior repositioning of the condyle in successful cases.¹⁸

Although individually the skeletal effects are not substantial, it is the sum total of all these effects which appears to provide a worthwhile gain in Class II correction.

Dentoalveolar effects of the twin block

The over-riding dentoalveolar effect of the TB is to cause mesial tipping of the lower dentition and distal tipping of the upper dentition.

The degree of proclination of the lower incisors varies depending on individual treatment response and appliance design, hence there is a lot of variation in the literature reports of proclination between 2 and 8 degrees.^{3, 12-17}

This variable treatment response is also mirrored in the upper labial segment, with anything between 2 and 14 degrees of retroclination occurring.^{3, 12-17} Such a variation in results should not be unexpected and may depend on the overall size of the overjet, original severity of incisor proclination and design and activation of the appliance.

The concomitant expansion of the upper arch with the TB midline screw will have similar effects to any other removable screw expansion appliance. The limited contact against the palatal surfaces leading to buccal tipping of the molars and premolars and dropping of the palatal cusps.¹⁹ Together with expansion the presence of the acrylic blocks inhibits eruption of buccal segment teeth, and results in substantial lateral open bites.

Effects of variation of appliance design

By modifying the design of the TB, it may be possible to reduce the amount of tooth tipping, but it does not seem possible to prevent it altogether.

In the upper arch, the addition of torquing spurs has been shown to reduce retroclination of upper incisors between 4 and 7 degrees.^{16,17} By ensuring adequate clasping for retention in the buccal segments, placement of a labial bow can be avoided and this may also limit upper incisor retroclination.

In the lower labial segment, the use of ball end clasps is thought to cause more proclination than acrylic capping, although as yet there are no reports on how this may alter the effectiveness of the appliance.

Advantages of the MBT™ System for the second phase of treatment

Large overjets that have been corrected with TBs have a tendency to relapse to a certain degree on withdrawal of the TBs. It is therefore a good idea to aim for over-correction to allow for an element of relapse. Although the TB is very effective at reducing large overjets it is less effective at correcting crowding and rotations and finalizing the tight interdigitation of the buccal segments. For this reason it is often necessary to carry out a phase of fixed appliance therapy following the initial TB phase.

The combined results of the skeletal and dentoalveolar effects in the successfully treated case will therefore often display the following clinical features in a typical Class II division 1 case. (Figure 1 and 2a-b)

14

- Incisors over-corrected to edge to edge
- Upper incisors have been retroclined
- Lower incisors have been proclined
- Molars over corrected to a Class III relationship
- Molars have been tipped buccally by expansion of the midline screw
- Lateral open bites

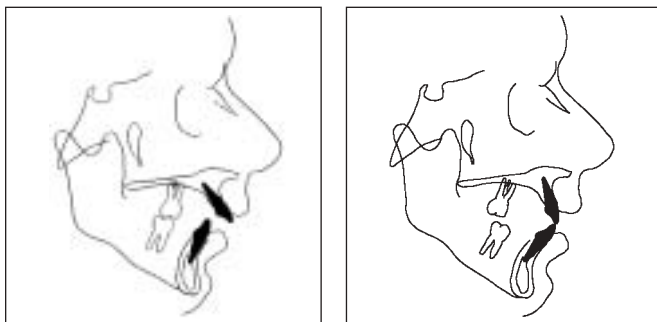


Figure 1: Schematic diagram to show the effects of the twin block appliance on the skeletal and dentoalveolar structures.

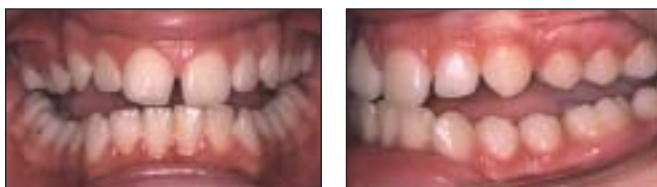

Figure 2a-b: Clinical views showing the typical appearance of the occlusion at the end of the twin block phase of treatment.

The aims of the fixed phase of treatment are to correct the residual crowding and rotations and to refine the occlusion to produce tight interdigitation of the buccal segments and coincident centre lines. It is often necessary to correct the over tipping of the teeth that has occurred during the TB phase of treatment.

The authors feel that the MBT™ Prescription offers significant advantages during the fixed phase of treatment. These advantages lie in four main areas²⁰:

- Incisor torque
- Posterior torque
- Incisor tip
- Posterior tip

Incisor Torque

The torque value for the upper central incisors is increased to 17° in the MBT prescription in comparison to 7° in the Andrew's prescription. The extra incisor torque is helpful to correct the palatal tipping of the incisors during the TB phase.

The torque value for the lower incisors is minus 6° in the MBT prescription in comparison to minus 1° in the Andrew's prescription. This extra labial root torque is useful in correcting the proclination of the lower incisors that tends to occur during the TB phase of treatment. (Figure 3)

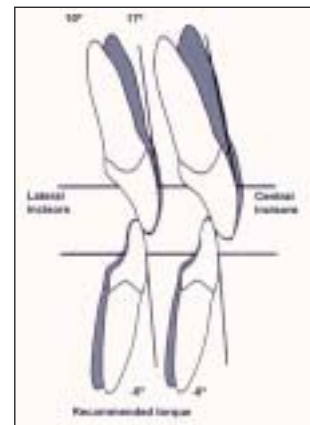


Figure 3: MBT™ Prescription incisor torque.

Posterior Torque

The torque value for the upper first molar is minus 14° in the MBT prescription in comparison to minus 9° in Andrew's prescription. This increased amount of buccal root torque is helpful in correcting the buccal tipping of the posterior teeth that occurs as a result of expansion of the TB's midline screw. (Figure 4)

Incisor Tip

On initial placement of fixed appliances following overjet reduction with a TB there is a tendency for the overjet to increase. This is in part due to the expression of the mesial tip in the prescription of most pre adjusted brackets. This undesirable increase in overjet can be partially reduced by the placement of lacebacks. The reduced anterior tip values in the MBT prescription are also helpful. (Figure 4)

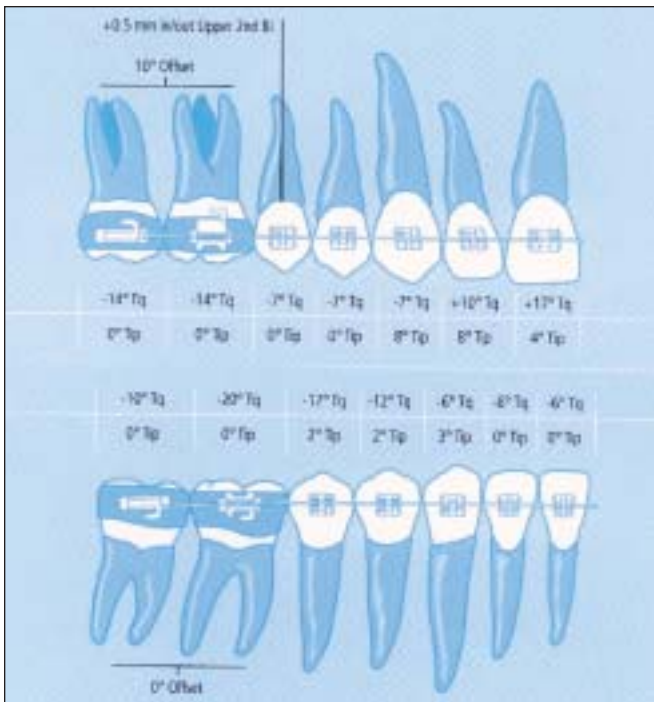


Figure 4: MBT™ Prescription tip and torque.

Posterior Tip

The tip values for the upper posterior teeth are 0°. This helps to prevent mesial tipping of the upper buccal segment teeth and so conserves the anchorage gained during the functional phase of treatment. The tip value for the lower premolars is 2°. This encourages a small amount of mesial tipping of the buccal segments so helping to maintain the correction of the buccal segments achieved during the functional phase.

From the above it can be seen that the MBT™ Prescription is remarkably complementary in achieving the necessary occlusal goals in converting a post TB result into a successfully finished case. (Figure 4)

Case CF – Case History

A female patient aged 12 years and 5 months presented complaining of “sticky out and gappy top teeth” with a moderate Class II division 1 malocclusion on a Class II skeletal base with a well-aligned lower arch and a spaced upper arch.

The overjet was 9mm and the overbite was increased and complete to the palate. In the buccal segments the right side was a full unit Class II and the left side was a half unit Class II. (Figure 5a-d and Figure 6a-e)

A TB with upper labial bow and lower incisor capping was fitted for full time wear. Overjet correction was obtained after 10 months of treatment. At this point TB wear was reduced to evening and night only to allow resolution of the lateral open bites. (Figure 7a-e)

Figure 5a-d: Case CF pre-treatment extra-oral views.

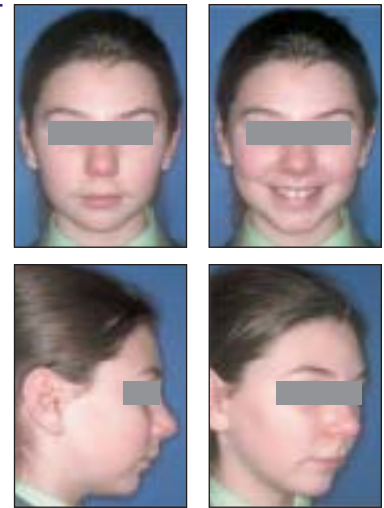

Figure 6a-e: Case CF pre-treatment intra-oral views.

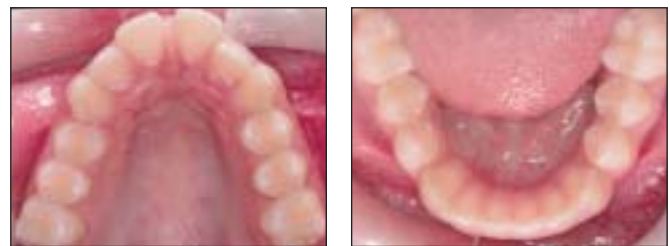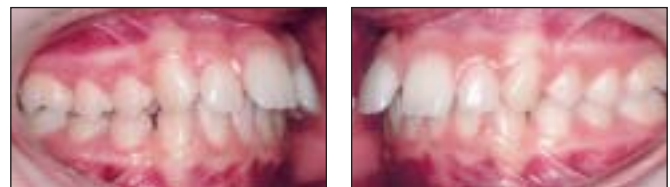
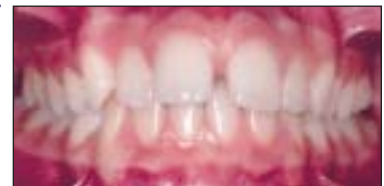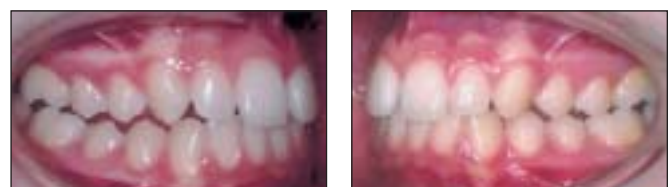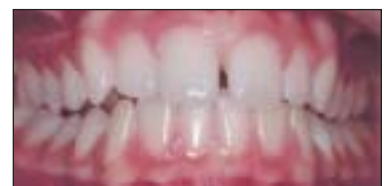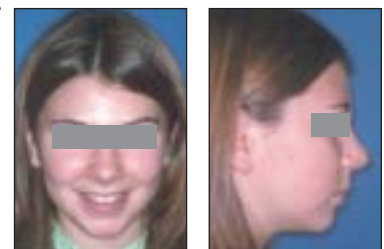


Figure 7a-e: Case CF post twin block views after 3 months of part-time wear to resolve lateral open bites.



In consultation with the patient and parent a second phase of treatment was planned on a non-extraction basis to align and level, provide appropriate torque, close residual space with center line correction and detail the occlusion. MBT™ Prescription bands and Victory Series™ Brackets were placed (Figure 8a-e), supported by use of a removable steep and deep bite plane. This appliance can be used to maintain the antero-posterior correction during the initial phase of alignment until progression to rigid stainless steel archwires allowing use of Class II elastics.²¹

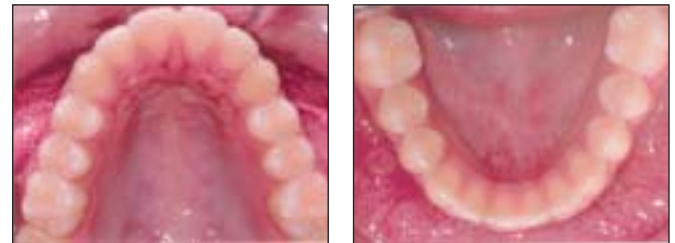
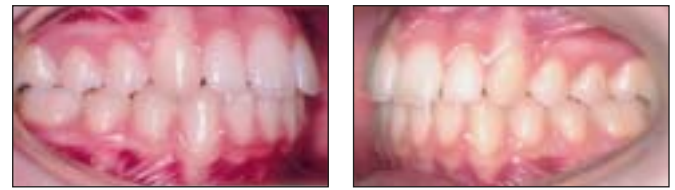
Appliances were debonded after a total treatment time of 2 years (Figure 9a-d and Figure 10a-e), and the patient fitted with removable retainers.

Figure 8a-e: Case CF in MBT™ Prescription fixed appliances during space closure.

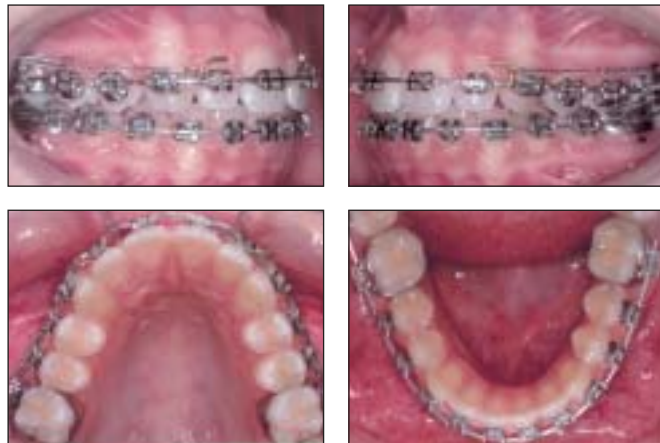
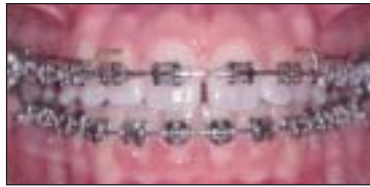
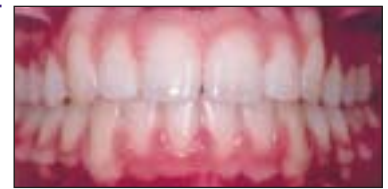Figure 9a-d: Case CF post-treatment extra-oral views.

Figure 10a-e: Case CF post-treatment intra-oral views.



Case CF – Treatment Effects

The patient presented with proclined and spaced upper incisors and the TB was designed with a labial bow to aid incisor retraction. This was very effective and retroclined the upper incisors by 10° (Table 2). The incisor torque was maintained during the fixed phase despite space closure as a result of the additional torque in the upper prescription and maintenance of an increased Curve of Spee in the upper archwire.

	Pre-treat	End Functional	Near end-treat
SNA	81°	81°	81°
SNB	75°	77°	78°
ANB	6°	4°	3°
LFH	55%	56%	56%
MMPA	28°	29°	29°
UI-MAX	120°	110°	113°
LI-MAND	90°	92°	90°

Table 2: Case CF pre-treatment, post-twin block and near end-treatment cephalometric values.

In the lower arch, the lower labial segment came forward only 2°, showing good control over incisor position by the use of labial segment capping. During the fixed appliance phase the additional lingual crown torque helped bring the incisors back to 90°.

In addition to the dental effects, the skeletal effects also mirror those described in the literature. The TB resulted in a 2° reduction in the ANB angle resulting from a reduction of the SNB angle. This reduction continued into the second phase of treatment i.e. suggesting that the resultant Class I finish was helped by continuation of the favourable growth pattern. (Figures 11a-c and Figure 12)

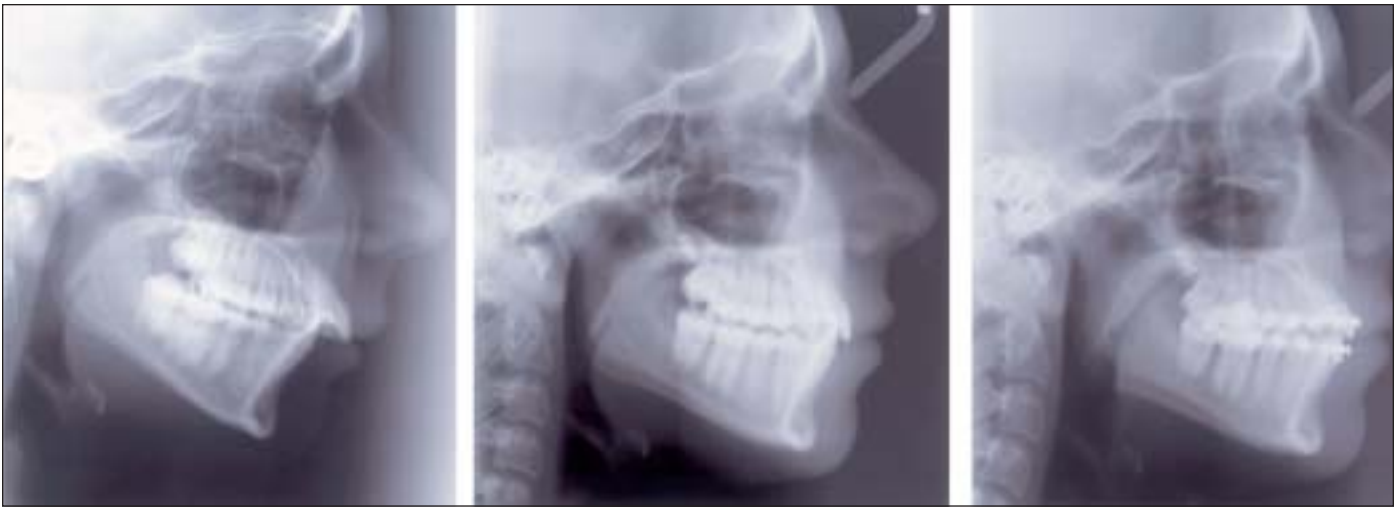

Figure 11a-c: Case CF pre-treatment, post-twin block and near end-treatment cephalograms.

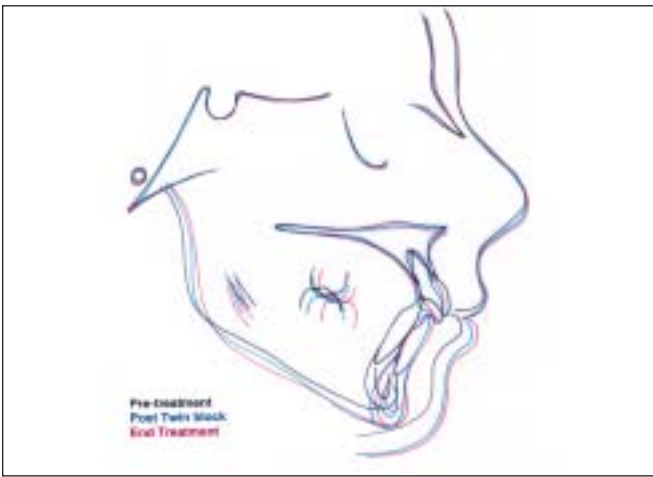

Figure 12: Case CF pre-treatment, post-twin block and near end-treatment cephalometric superimpositions.

Acknowledgements

The authors would like to acknowledge Miss Margaret Evans who was involved in the treatment of the presented case. ■

REFERENCES

- Chadwick SM., Banks P, Wright, JL. The use of myofunctional appliances in the UK: a survey of British orthodontists. *Dent Update* 1998; 25(7):302-308.
- Clark WJ. The twin block traction technique. *Eur J Orthod* 1982;4:129-138.
- Clark WJ. The twin block technique. A functional orthopedic appliance system. *Am J Orthod Dentofac Orthop* 1988;93:1-18.
- Scholey J. The British Orthodontic Society Medal of the Intercollegiate MOrth of the Royal College of Surgeons of London and Glasgow 2001 and the William Houston Medal of the MOrth of the Royal College of Surgeons of Edinburgh 2001. *J Orthod* 2002; 29: 83-95.
- Dyer FMV, McKeown H F, Sandler PJ. The modified twin block appliance in the treatment of Class II division 2 malocclusions. *J Orthod* 2001;28:271-280.
- Cureton SL., Regennitter FJ., Yancey JM. Clinical versus quantitative assessment of headgear compliance. *Am J Orthod Dentofac Orthop.* 1993 104(3):277-284
- Samuels RH., Willner F. Knox J. Jones ML. A National survey of orthodontic facebow injuries in the UK and Eire. *Br J Orthod.* 1996;23:11-20.
- Tulloch JF., Phillips C., Koch G., Proffit WR. The effect of early intervention on skeletal pattern in Class II malocclusion: a randomized clinical trial. *Am J Orthod Dentofac Orthop* 1997;111(4):391-400.
- Keeling SD, Wheeler TT., King GJ., Garvan CW., Cohen DA, Cabassa S, et al. Anteroposterior skeletal and dental changes after early Class II treatment with bionators and headgear. *Am J Orthod Dentofac Orthop* 1998;113:40-50.
- Bishara SE., Ziaja RR. Functional appliances: a review. *Am J Orthod Dentofac Orthop* 1989;95(3):250-258.
- O' Brien et al. The effectiveness of early orthodontic treatment with the twin block appliance. A multi-centre randomised controlled trial. Part One Dental and Skeletal effects. *Am J Orthod Dentofac Orthop.* In press.
- Lund I., Sandler PJ. The effects of twin blocks: a prospective controlled study. *Am J Orthod Dentofac Orthop* 1998;113:104 -110
- Mills C, McCulloch KJ. Treatment effects of the twin block appliance: a cephalometric study. *Am J Orthod Dentofac Orthop* 1998;114:15-24.
- Illing HM., Morris DO., Lee RT. A prospective evaluation of Bass, Bionator and twin block appliances. Part 1 – The hard tissues. *Eur J Orthod* 1998;20:501-516.
- Trenmouth MJ. Cephalometric evaluation of the twin block appliance in the treatment of Class II division 1 malocclusion with matched normative growth data. *Am J Orthod Dentofac Orthop* 2000;117:54-59.
- Harradine NWT., Gale D. The effects of torque control spurs in twin block appliances. *Clin. Orthod. Res.* 2000;3:202-209.
- Parkin NA., McKeown HF, Sandler PJ. Comparison of 2 modifications of the twin block appliance in matched Class II samples. *Am J Orthod Dentofac Orthop* 2001;119:572-577
- Chintakanon K., Sampson W., Wilkinson T., Townsend G. *Am J Orthod Dentofac Orthoped* A prospective study of twin block appliance therapy assessed by magnetic resonance imaging. 2000 Nov 118;5:494-504.
- Herold JS. Maxillary expansion: A retrospective study of three methods of expansion and their long term sequelae. *Br J Orthod.* 1989;16(3):195-200.
- McLaughlin., Bennett., Trevisi. *Systemized orthodontic treatment mechanics.* 2002 Mosby Press.
- Sandler, J., DiBiase D. The inclined biteplane - a useful tool. *Am J Orthod Dentofac Orthoped* 1996;110:339-350.

Orthodontic Treatment Using The Dental VTO And MBT™ System

by Dr. Hideyuki Iyano



Dr. Hideyuki Iyano, Department of Orthodontics, Ohu University School of Dentistry, Japan. He is also a member of the Japan MBT™ System Study Group.

Having many cases with severe crowding in Japan, we tend to level the dental arches after premolar extraction. This often results in tipping of the adjacent teeth into the extraction site, slowing the leveling process and causing the anterior teeth to elongate due to the angulation built into the canine bracket in a preadjusted appliance system. In principle, .016 and .019 X .025 HANT wires with the anterior form of the arch wire matching the patient's arch form should be sequentially used to level the buccal segments and canine bracket slots before proceeding to premolar extraction and bracketing of the anterior teeth.

18

In the MBT™ System, .019 X .025 stainless steel wires are used as final arch wires to correct the upper and lower dental midlines and close remaining spaces by sliding mechanics. This necessitates the analysis of the direction and amount of tooth movements in each quadrant to make an extraction/non-extraction decision and select appropriate anchorage.

The Dental VTO devised by McLaughlin, et al., is a useful diagnostic tool that enables clinicians to plan treatment and manage tooth movements during treatment. Two cases treated with the MBT system based on the Dental VTO will be presented.

Charting of the Dental VTO

This analysis consists of three charts:

Chart 1 (Initial Midline and Molar Position) records initial midline and first molar positions. These must be recorded with the mandible in centric relation.

Chart 2 (Lower Arch Discrepancy) records the lower arch discrepancy. Six primary lower arch factors, ① through ⑥, are estimated and recorded separately from canine to midline and from second molar to midline on each side. These values are then added to obtain the initial discrepancies a1, a2, A1 and A2.

Four secondary factors (⑦ through ⑩), which are sometimes used to gain additional space, are then recorded from canine to midline and from second molar to midline on each side and added up to derive the remaining discrepancies b1, b2, B1 and B2 for the respective segments.

Chart 3 (Anticipated Treatment Change, VTO) records anticipated direction and amount of movements relative to first molars, canines and midline correction.

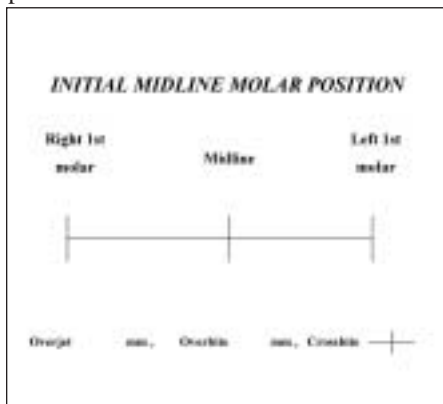


Chart 1




Chart 2




Chart 3

Initial crowding/spacing in the lower arch

1. Crowding/spacing from canine to midline on each side
2. Crowding/spacing in the premolar area
3. Crowding/spacing in the molar area
4. Space required for Curve of Spee leveling
5. Space required for midline correction
6. Space required for desired correction of protrusion or retrusion of the lower incisors

Initial discrepancies

- a1: Crowding/spacing from right canine to midline
- a2: Crowding/spacing from left canine to midline on
- A1: Crowding/spacing from right second molar to midline
- A2: Crowding/spacing from left second molar to midline

Spaces expected to be gained with treatment

7. Additional space from interproximal enamel stripping
8. Additional space from expansion
9. Additional space from uprighting or distal movement of lower first molars
10. Additional space from extraction

Remaining discrepancies

- b1: Crowding/remaining space from right canine to midline
- b2: Crowding/remaining space from left canine to midline
- B1: Crowding/remaining space from right second molar to midline
- B2: Crowding/remaining space from left second molar to midline

Figure 1




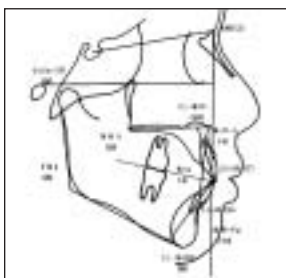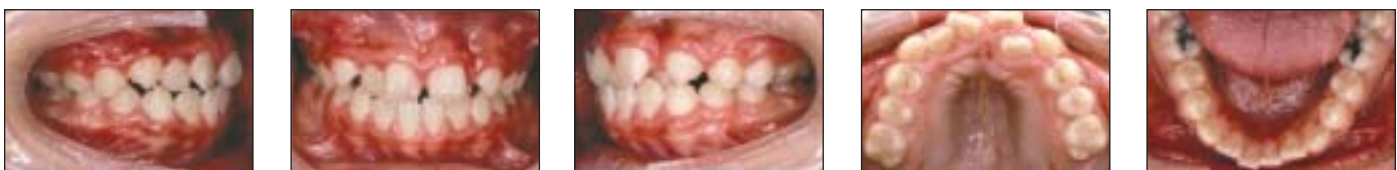


Figure 2

Figure 3

Figure 4

Figure 5

Case 1: A crowding case with mesial displacement of the upper left first molar

Hideyuki Iyano, Department of Orthodontics, Ohu University School of Dentistry

Diagnosis and treatment plan

An 11 year 6 month old male presented with crooked anterior teeth (Fig. 1). The upper left lateral incisor was palatally displaced. His molar relationship was Angle Class II on the left side. There was 1.0mm of crowding in the lower left anterior area. The lateral cephalogram showed ANB of 2°, Wits of -4.0mm and no abnormality of A-P jaw relationship (Fig. 2). The inclination of the upper incisor was within a normal range, while the lower incisor was inclined labially. The upper left first molar was displaced 3mm mesially (Fig. 3). The upper midline was deviated 2mm to the left.

The above lower arch information was recorded on chart 2 (Fig. 4). From the primary factors for the lower anterior segment such as crowding, Curve of Spee and midline deviation, the initial discrepancy from canine to midline was calculated to be -2.0mm on the right side and -1.0mm on the left side. The initial discrepancy for the entire lower arch thus totaled -2.0mm on the right side and -1.0mm on the left side.

Diagnosis: Crowding with mesial displacement of the upper left first molar.

Dental VTO: Additional space from expansion of the lower arch with a full appliance was estimated to be 2.0mm for the right anterior area, 1.0mm for the left anterior area, 2.0mm for the right side of the whole arch, and 1.0mm for the left side of the whole arch.

A decision was made to distalize the upper left first molar 3.0mm and move the upper dental midline 2mm to the right in order to create space for the palatally displaced upper left lateral incisor (Fig. 5).

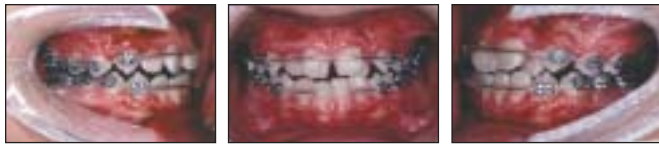

Figure 6

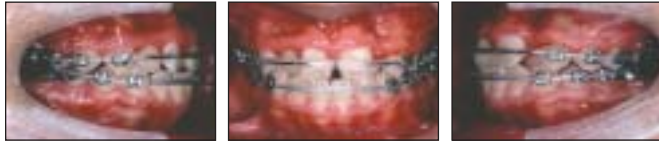

Figure 7

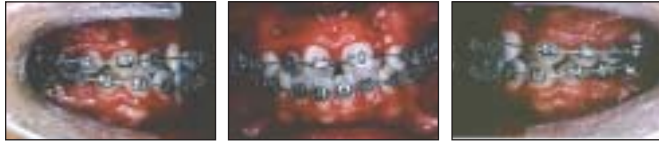

Figure 8

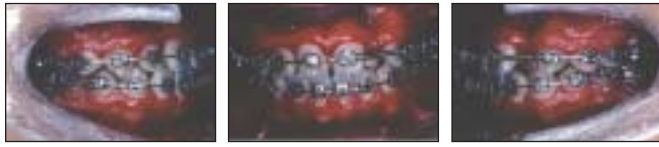

Figure 9

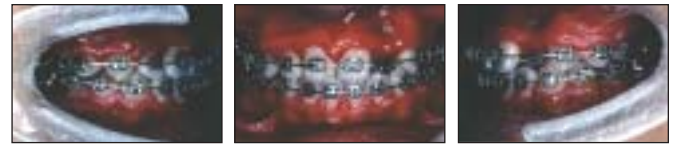

Figure 10



Figure 11

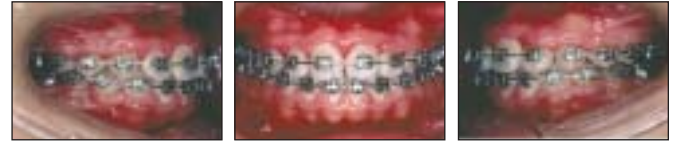

Figure 12

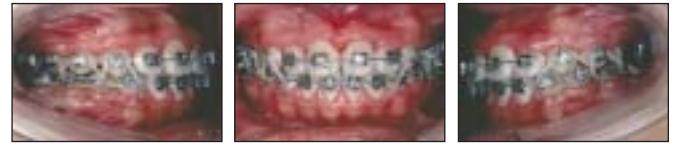

Figure 13

Course of treatment and results

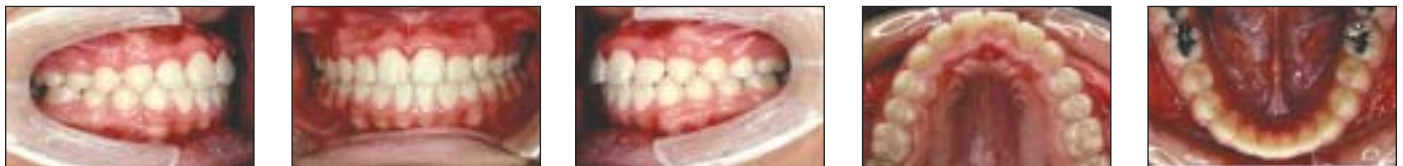A unilateral headgear was used for 4 months, resulting in 4mm distal movement of the upper left first molar. As Class I molar relationship was established on the left side, full appliance treatment was initiated. Three types of arch wires were used during treatment: .016 HANT wires, .019 X .025 HANT wires and .019 X .025 SS wires, all in OrthoForm™ III (ovoid type).

Upper and lower .016 HANT wires were placed to level the lower canines with lacebacks (Fig. 6). With the placement of upper and lower .019 X .025 HANT wires, the buccal segments were leveled and the overbite was closed (Fig. 7, 1 mo.). The upper and lower anterior teeth except the upper left lateral incisor were bracketed (Fig. 8, 2 mo.). Upper and lower .019 X .025 SS wires

were inserted, and an open coil spring was used to gain space for the upper left lateral incisor (Fig. 9, 4 mo.). The upper left lateral incisor bracket was placed upside down (Fig. 10, 5 mo.). The palatally displaced upper lateral incisor was moved labially into the arch by under-laying the .016 HANT wire. In the upper arch, a .019 X .025 HANT wire was placed (Fig. 11, 6 mo.), followed by a .019 X .025 SS wire (Fig. 12, 12 mo.). After the upper lateral incisor was torqued adequately, the settling process was initiated (Fig. 13, 13 mo.). Active treatment time was 14 months (Fig. 14, 15, 16). The post-treatment panoramic X-ray shows that root paralleling has been accomplished.

The torque of the palatally displaced upper left lateral incisor was effectively controlled with the inverted bracket.

Figure 14



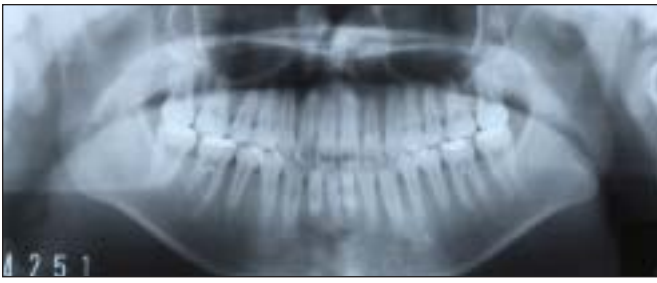

Figure 15

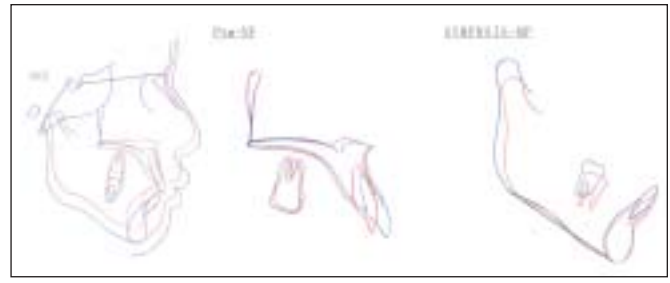


Figure 16

Case 2: A functional anterior crossbite case

Hideyuki Iyano, Hideki Ogawa, Department of Orthodontics, Ohu University School of Dentistry

Diagnosis and treatment plan

A 13 year 3 month old female presented with a crossbite. The anterior teeth were in crossbite (Fig. 17). Her molar relationship was Angle Class I. The lateral cephalogram showed that the mandible was in front of the maxilla with ANB of -2.0° and Wits of -8.0mm (Fig. 18). The inclinations of the upper and lower incisors were 124.0° and 94.0° , respectively, both being labially inclined. The upper dental midline was deviated 2.0mm to the left (Fig. 19). The Curve of Spee was 2.0mm. Her arch showed 1.0mm of crowding in the lower premolar area on each side.

These numbers were entered into chart 2 (Fig. 20). The initial discrepancy for the lower anterior segment consisting of incisor position, crowding, Curve of Spee and midline deviation amounted to -3.0mm on the right side and -3.0mm on the left

side. The initial discrepancy for the entire lower arch totaled -4.0mm on the right side and -4.0mm on the left side.

Diagnosis: Functional anterior crossbite

Dental VTO: Extraction of four first premolars was required due to the amount of discrepancy. The lower central incisors needed to be retracted 3.0mm. The analysis also called for 3.0mm of lower canine retraction on each side and 3.3mm of mesial movement of the lower first molar on each side. The upper first molars needed to be moved forward 3.3mm per side in order to maintain Angle Class I molar relationship.

It was decided to shift the upper midline 2mm to the right (Fig. 21).

21

Figure 17

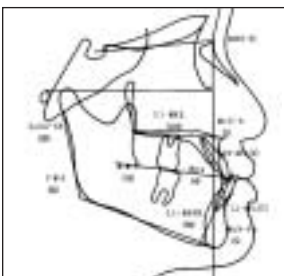
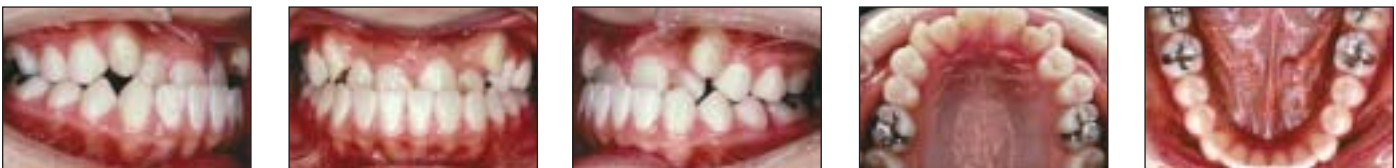

Figure 18




Figure 19



Figure 20




Figure 21

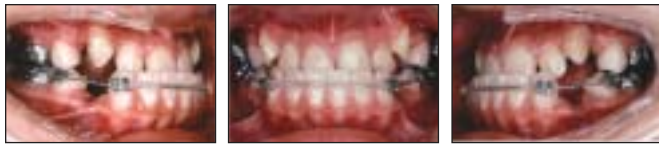

Figure 22

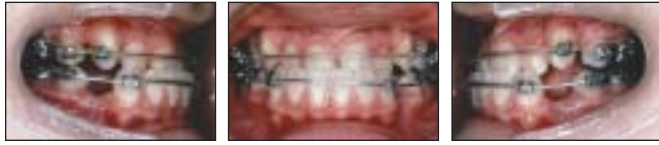

Figure 23

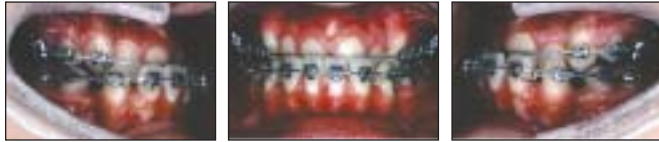

Figure 24

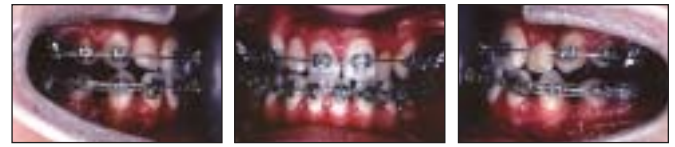

Figure 25

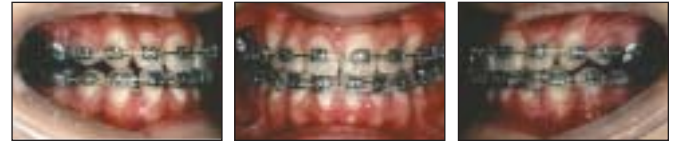

Figure 26

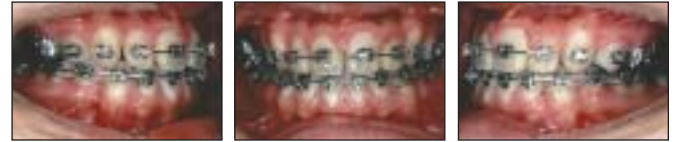

Figure 27

Course of treatment and results

Three types of arch wires were used during treatment: .016 HANT wires, .019 X .025 HANT wires and .019 X .025 SS wires, all in OrthoForm™ III (ovoid type). A Nance holding arch was placed in the upper, while the lower arch was started with a .016 HANT wire (Fig. 22). Considering the need to intrude the lower incisors, the lower buccal segments were leveled first, followed by leveling of the lower canines with lacebacks. An upper .016 HANT wire and a lower 019 X .025 HANT wire were then placed (Fig. 23, 2 mo.). These wires were replaced with an upper 019 X .025 HANT wire and a lower 019 X .025 SS wire (Fig. 24, 8 mo.). Following the intrusion of the lower incisors, which was accomplished in 2 months, the upper incisors were

bracketed (Fig. 25). Midline correction was initiated after overbite improvement (Fig. 26, 16 mo.). After one month of settling, active treatment was completed in 23 months (Fig. 28, 29, 30). The post-treatment panoramic X-ray shows that root paralleling has been achieved. The use of lacebacks for lower canine retraction minimized anchorage loss of the molars.

Summary

The Dental VTO was found to be a useful aid in diagnosis, treatment planning and management of three-dimensional tooth movements at chairside. ■

Figure 28

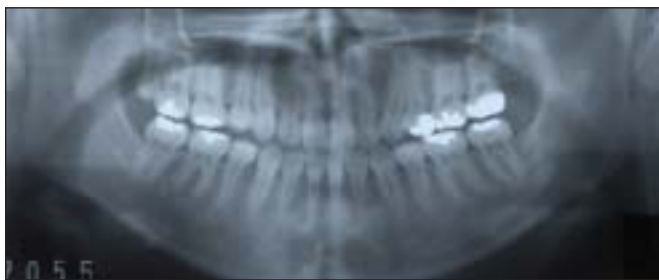
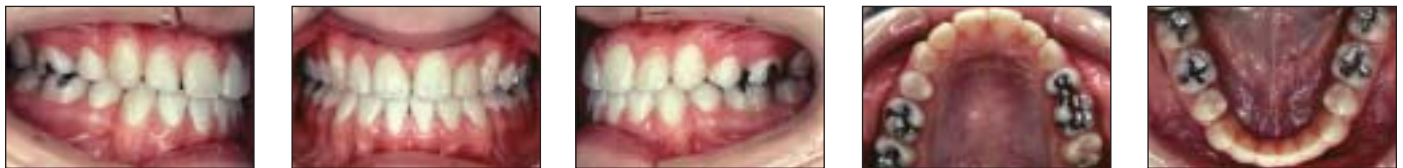
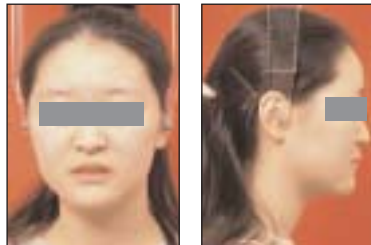Figure 29

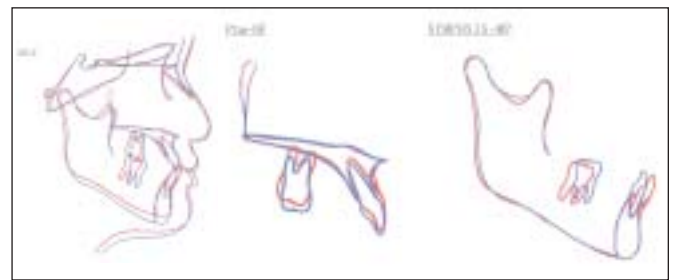


Figure 30

22

• The Art of Dolphin Imaging's Arnett/McLaughlin Interactive Treatment Analysis

Part II. The McLaughlin Dental VTO™

by Chester Wang



Mr. Chester Wang is a pioneer member at Dolphin Imaging and has been the managing director of Dolphin since 1996. Mr. Wang lectures and works extensively with orthodontic practices worldwide on effectively utilizing technology. Prior to Dolphin, Mr. Wang was a software engineer at Xerox and IBM and received his Bachelor of Science in Mathematics and Computer Science from the University of California in Los Angeles.

Dolphin Imaging's newest software release is the Arnett/McLaughlin Interactive Treatment Analysis. Designed by Dr. G. William Arnett and Dr. Richard McLaughlin, the software consists of two treatment planning modules that incorporate proven principles from thousands of cases and years of clinical experience. The software was developed as part of a strategic alliance between Dolphin and 3M Unitek, and is fully compatible with the MBT™ Appliance System. The previous article provided a sample using the Arnett Soft Tissue Analysis module. This issue summarizes the capabilities of the McLaughlin Dental VTO™ module using another case sample.

When used in conjunction with the Arnett Soft Tissue module, the McLaughlin Dental VTO provides crucial details concerning the movement of midlines, canines and molars in any given case. This powerful program can be used for orthodontic or surgical-orthodontic cases.

The McLaughlin Dental VTO program utilizes 3 "Wizard" charts to guide you through the treatment planning process. Its use is best explained with an example orthodontic case provided by Dr. Richard McLaughlin. Our patient is a 27 year old female with a slight Class III skeletal pattern. Her panoramic radiograph, cephalometric radiograph and cephalometric tracings are shown. (Figure 1, 2, 3, 4)

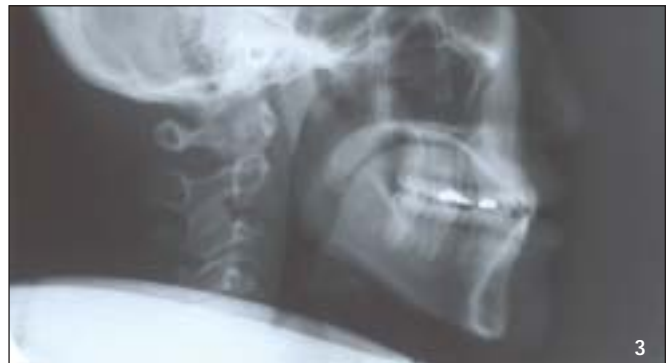

Figure 3: Cephalometric radiograph.

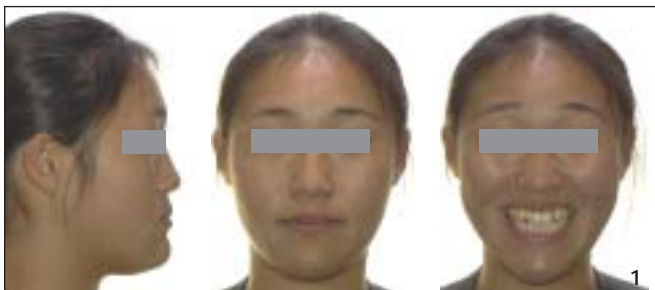

Figure 1: Facial images of the patient.



Figure 2: Panoramic radiograph.

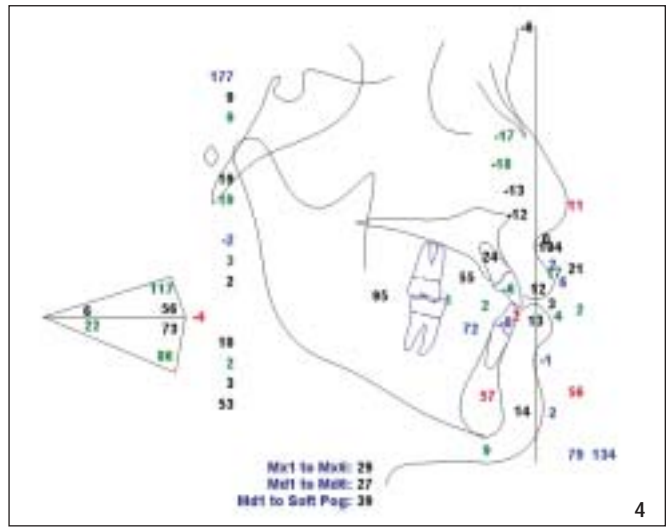


Figure 4: Cephalometric tracing.

Initial Position: Molars, Midlines (Chart 1)

Chart 1 in the Dental VTO is used to record initial values of midline and molar relationships. (Figure 5) All recordings are taken with the mandible in centric relation (CR). If midline deviations exist, and a decision is made to correct the deviations with dental compensation, the amount of correction is indicated here. The patient's intraoral images are automatically displayed in this chart. Images can be enlarged with a single click on the image. This patient shows a Class I dental relationship, a slight deviation of her midlines to the left side and molars that are Class I on each side. The upper dental midline is 2 mm to the left and the lower dental midline is 1 mm to the left. (Figure 5)

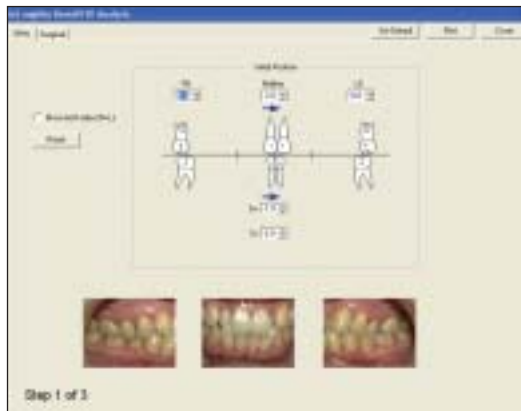


Figure 5: Chart 1 of the Dental VTO.

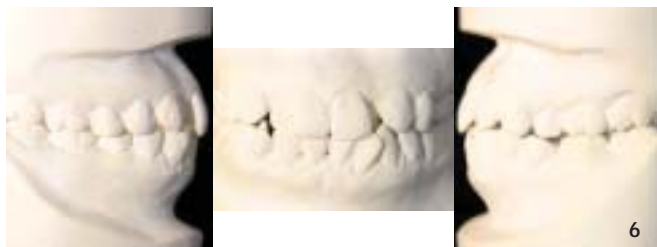


Figure 6: Right, center and left views of the study models.

Lower Arch Discrepancy (Chart 2)

Chart 2 is designed to record, in detail, the lower arch discrepancies and to indicate any preliminary treatment. This chart is organized in a "3 to 3" column, for factors occurring from canine to canine, and a "7 to 7" column, for factors occurring in the entire lower arch.

In the lower anterior segment, the patient shows 2 mm of crowding on the right and 4 mm of crowding on the left (Figure 7). This value is recorded in **C/S Anterior**. A negative number indicates crowding and a positive number indicates spacing. The amount indicated is immediately reflected in the graphical diagram for verification. This patient also shows 1 mm of crowding in the left bicuspid region (**C/S Bicuspid/E**), no crowding in the molar areas (**C/S Molars**) and a level plane of occlusion (**Curve of Spee**).

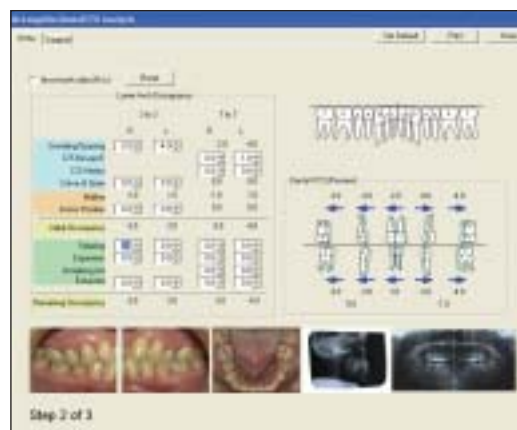


Figure 7: Intraoral views, radiographs and the initial information recorded in Chart 2.

Values in the dental **Midline** field are automatically transferred from Chart 1 and the anterior or posterior movement of the incisor is recorded in **Incisor Position**. The incisor position the movement is based on the Arnett STCA™. Dr. McLaughlin assumes one mm of anterior movement to provide one mm of space per side. For our patient, the lower midline needed to move 1 mm to the right and a decision was made to move the lower incisors 1 mm distally, due to the Class III skeletal tendency.

A net discrepancy is automatically calculated in **Initial Discrepancy** (Figure 8). With possible interproximal reduction (**Stripping**), inter-canine or molar expansion (**Expansion**) or upright/distalizing of the first molars (**Distalizing 6-6**), the initial discrepancy determines whether non-extraction or extraction treatment is indicated.

	3 to 3		7 to 7	
	R	L	R	L
Crowding/Spacing	-2.0	-4.0	-2.0	-4.0
C/S Bicuspid/E			0.0	-1.0
C/S Molars			0.0	0.0
Curve of Spee	0.0	0.0	0.0	0.0
Midline	-1.0	1.0	-1.0	1.0
Incisor Position	-1.0	-1.0	-1.0	-1.0
Initial Discrepancy	-4.0	-4.0	-4.0	-5.0

Figure 8: Information recorded down to the completion of the initial discrepancy.

For any planned extractions, click the appropriate tooth in the upper-right arch diagram. Any operation can easily be undone. Spaces gained due to extractions are recorded automatically under **Extraction**. Overriding of values can also be done by manually altering the appropriate fields. For the patient, because of her significant crowding, a decision was made to extract four first bicuspids.

The net result of Chart 2 is **Remaining Discrepancy**, which is the net initial discrepancy recorded plus any spaces gained by the indicated treatment (stripping, expansion, etc). For the patient,

the **Remaining Discrepancy** shows -4mm per side under the “3 to 3” column, which means that the lower canines need be retracted (Figure 9). This indication is also automatically depicted in the **Dental VTO (Preview)** diagram. This intuitive graphical diagram is the power of the Dental VTO program.

	3 to 3		7 to 7	
	R	L	R	L
Crowding/Spacing	0.0	-4.0	2.0	-4.0
C/S Bouq/E			0.0	-1.0
C/S Molar			0.0	0.0
Curve of Spee	0.0	0.0	0.0	0.0
Midline	-1.0	1.0	-1.0	1.0
Incisor Position	-1.0	-1.0	-1.0	-1.0
Initial Discrepancy	-4.0	-4.0	-4.0	-5.0
Stripping	0.0	0.0	0.0	0.0
Expansion	0.0	0.0	0.0	0.0
Distalizing 6-6	0.0	0.0	0.0	0.0
Extraction	0.0	0.0	7.0	7.0
Remaining Discrepancy	-4.0	-4.0	3.0	2.0

Figure 9: Completion of Chart 2; the decision was made to extract four first bicuspids.

Dental VTO (Proposed Dental Movement) (Chart 3)

Chart 3 provides the automated final treatment proposal, but allows for further tooth movement decisions. The graphical diagram clearly shows the direction of the proposed movement (right, left, mesial, distal) and its corresponding amount for the midlines, canines and molars. All values can be overridden if desired.

The values located between the respective canine and molar movement numbers are premolar/molar spaces. They represent the original spacing or crowding in the premolar/first molar region, as well as any space gained as a result of extractions, stripping, expansion or distalizing of the first molars.

Final calculations on the dental changes for the patient are in Figure 10. According to the proposed treatment,

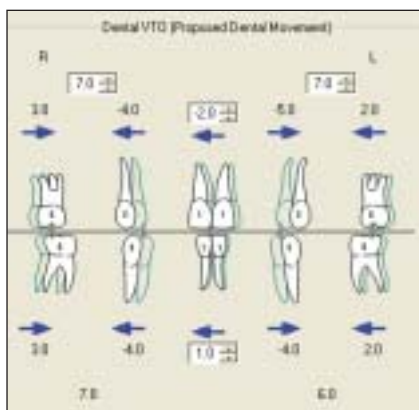


Figure 10: Chart 3 shows the anticipated treatment changes for the midlines, canines and molars. The computer program is capable of graphically illustrating these changes.

The patient’s final records are shown in Figure 11. According to Dr. McLaughlin’s treatment documentations, the incisors were retracted 1 mm because of the Class III skeletal tendency and to provide a balanced profile. The dentition was positioned behind the incisors on an extraction basis.

The McLaughlin Dental VTO™ provides a powerful and intuitive tool for orthodontists to precisely treatment plan a case. It is designed to be used with the Arnett Soft Tissue Analysis. ■

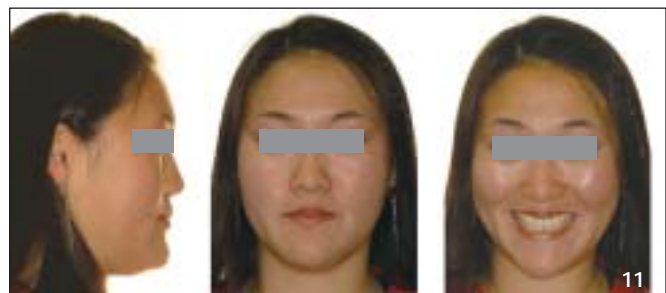
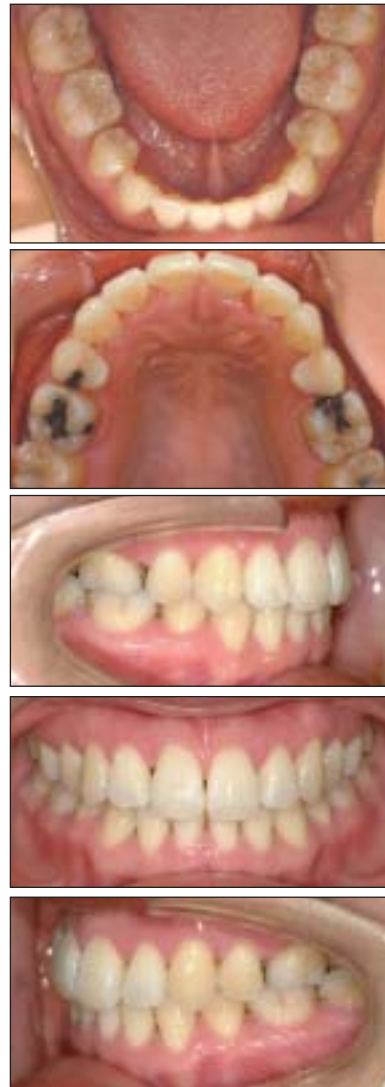
Figure 11: Final records of the case, showing that the incisors were placed in the face to provide a balanced profile, and the dentition was positioned behind the incisors on an extraction basis.

THE BOTTOMLINE

Successful Strategies For Private Practice Orthodontists®



resident's program

Today's orthodontic residents are well prepared clinically. However, few are adequately trained for the challenges of initiating and managing their practices. The Bottom Line University Programs® prepare students for the real world challenges that they will face. Information and guidance on securing financing for a start-up practice, developing and managing a comprehensive marketing program, and developing referral relationships are but a few of the subjects that will be presented. You will learn how to grow at exponential rates while avoiding common graduate mistakes and capitalizing on the opportunities that you may not know exist. This program is a must for every orthodontic resident.

The Bottom Line University Programs®

October 18-19, 2003
Columbus, OH

October 25-26, 2003
St. Louis, MO

November 1-2, 2003
Dallas, TX



one-day seminars

How can you evaluate the value of our Comprehensive Series or Study Group? To answer this question we have developed The Bottom Line One-Day Programs® that will highlight the fundamental concepts of The Bottom Line – *Successful Strategies For Private Practice Orthodontists®*. Available to individual orthodontists, office managers and interested orthodontic groups, the One-Day Programs will provide you with new information and new insights on achieving the highest level of personal and practice success. You see, setting goals and seeking excellence in management, marketing, and training, all impact your bottom line. This could very well be the most valuable seminar that you have ever attended. Spend the day with us and prepare to be inspired.

The Bottom Line One-Day Programs® (For Practicing Doctors)

Doctor & Key Staff Program
May 3, 2003
AAO ~ Hawaii

Doctor Program
May 5, 2003
AAO ~ Hawaii

Doctor & Key Staff Program
September 12, 2003
Orlando, FL



comprehensive series

There are few qualified sources today for an orthodontist seeking information on the business aspects of private practice. Existing practitioners facing important decisions on how to grow, become more efficient, become more profitable, while simultaneously improving excellence are similarly hampered. Recent graduates are forced to learn by unguided research, trial and error, or if lucky, by a mentor. The Bottom Line Comprehensive Series® will teach you how to set practice goals and give you the tools to achieve them. It will teach you how to develop a patient-centered practice, driven to excellence that is simultaneously fun and hugely profitable. The Comprehensive Series consists of four, 4-day weekend sessions, spread out over a year. On completion of the series, participating doctors become eligible for membership in The Bottom Line Study Group®.

2003 – 2004 The Bottom Line Comprehensive Series® (One Series Per Year)

Session I: November 6-10, 2003
Gurnee, IL

Session II: March 11-15, 2004
Palm Desert, CA

Session III: June 2004
Gurnee, IL

Session IV: Autumn 2004
To be determined



study group

Wouldn't it be nice to belong to a study group of respected colleagues that you could share ideas with on how to excel as practitioners as well as businessmen/women? Imagine a forum where private practice orthodontists could share ideas on staffing, scheduling, management, practice transition, marketing, or achieving financial security. Imagine a forum for sharing new ideas in diagnosis or techniques in treatment that will make your results more stable, your treatment shorter, your treatment more profitable, and your patients happier. If these concepts appeal to you, then The Bottom Line Study Group® is right for you. Completion of The Comprehensive Series is required for eligibility to join The Study Group.

The Bottom Line Study Group®

May 9-10, 2003
Kauai, Hawaii

For more information, an informative (free) CD, or to register for the comprehensive series or the study group, please contact Ms. Kelly Buchman at 1-877-ORTHO34.

The Bottom Line – *Successful Strategies For Private Practice Orthodontists, University Programs, One-Day Programs, Comprehensive Series and Study Group* are registered trademarks of Terry A. Sellke, D.D.S., M.S.

Continuing Education Schedule

Products that make your life easier.

DATE	SUBJECT	PRESENTER(S)	LOCATION
5/19/03	Utilizing the MBT™ Appliance System To Facilitate Interdisciplinary Treatment	Dr. Jackie Berkowitz	Nebraska Ortho Society Omaha, NE
6/6/03	Utilizing the MBT™ Appliance System To Facilitate Interdisciplinary Treatment	Dr. Jackie Berkowitz	Case Western Reserve Cleveland, OH
6/20/03	Diagnosis, Treatment Planning and Treatment Mechanics	Dr. Richard McLaughlin	San Diego, CA
6/26/03-6/27/03	"Full Arch Indirect Bonding – MBT™ Rx" – In-Office Seminar	Dr. John Kalange	Boise, ID
6/30/03-7/2/03	SUMMIT at the Greenbrier	Dr. Richard McLaughlin Dr. G. William Arnett	Greenbrier, West VA
7/13/03-7/16/03	MBT™ System – In-Office Seminar	Dr. Richard McLaughlin Dr. Terry McDonald	San Diego, CA
7/24/03-7/25/03	"Full Arch Indirect Bonding – MBT™ Rx" – In-Office Seminar	Dr. John Kalange	Boise, ID
8/1/03	World Ortho Congress	Dr. Richard McLaughlin Dr. Anoop Sondhi	San Diego, CA
9/5/03-9/6/03	"The Essence of Efficiency" – In-Office 2-Day Seminar	Dr. Anoop Sondhi	Indianapolis, IN
9/12/03	The Bottom Line – One-Day Programs* for Practicing Doctors and Key Staff	Dr. Terry Sellke Mr. Bill Poss	Orlando, FL
9/18/03-9/20/03	"Full Arch Indirect Bonding – MBT™ Rx" – In-Office Seminar	Dr. John Kalange	Boise, ID
9/19/03-9/20/03	MBT™ System – MW Region Course V	Dr. Richard McLaughlin	To be determined
10/3/03-10/4/03	"The Essence of Efficiency" – In-Office 2-Day Seminar	Dr. Anoop Sondhi	Indianapolis, IN
10/18/03-10/19/03	The Bottom Line – University Programs* – 2-Day Seminar	Dr. Terry Sellke Dr. John McDonald Dr. Robert Norris Dr. Tom Ziegler Mr. Bill Poss	Columbus, OH
10/24/03-10/25/03	SUMMIT in New Orleans	Dr. Richard McLaughlin Ms. Lori Garland Parker	New Orleans, LA
10/25/03-10/26/03	The Bottom Line – University Programs* – 2-Day Seminar	Dr. Terry Sellke Dr. John McDonald Dr. Robert Norris Dr. Tom Ziegler Mr. Bill Poss	St. Louis, MO
11/1/03-11/2/03	The Bottom Line – University Programs* – 2-Day Seminar	Dr. Terry Sellke Dr. John McDonald Dr. Robert Norris Dr. Tom Ziegler Mr. Bill Poss	Dallas, TX
11/2/03-11/5/03	MBT™ System – In-Office Seminar	Dr. Richard McLaughlin Dr. Terry McDonald	San Diego, CA
11/6/03-11/10/03	The Bottom Line – Comprehensive Series* USA – Session I	Dr. Terry Sellke	Gurnee, IL
2/15/04-2/18/04	MBT™ System – In-Office Seminar	Dr. Richard McLaughlin Dr. Terry McDonald	San Diego, CA
3/12/04-3/13/04	"The Essence of Efficiency" – In-Office 2-Day Seminar	Dr. Anoop Sondhi	Indianapolis, IN
4/2/04-4/3/04	SUMMIT in Las Vegas	Dr. Richard McLaughlin	Las Vegas, NV
4/16/04-4/17/04	"The Essence of Efficiency" – In-Office 2-Day Seminar	Dr. Anoop Sondhi	Indianapolis, IN
7/18/04-7/21/04	MBT™ System – In-Office Seminar	Dr. Richard McLaughlin Dr. Terry McDonald	San Diego, CA

27

For more information, please call the 3M Unitek CE HOTLINE at 1-800-852-1990 ext. 4649 or 626-574-4649. Or, visit the Professional Relations/Continuing Education page on the 3M Unitek web site at www.3MUnitek.com.

THE BOTTOMLINE

Australia/New Zealand Group Dates

Successful Strategies For Private Practice Orthodontists*

9/17/03	The Bottom Line University and 1-Day Practicing Doctor Program*	Sydney, Australia
1/30/04*	The Bottom Line University and 1-Day Practicing Doctor Program*	Auckland, New Zealand

For more information on the Australia/New Zealand courses, please call The Bottom Line at (847) 223-2836 or Ms. Gabriele West, Product Manager, 3M Unitek Australia at (61) 2 9875 6370.

* date and location subject to change

Summit 2003

Plan for a great year of Summits from 3M Unitek

March



March 7~8, 2003
Monte Carlo Hotel – Las Vegas
Great Meeting!

June/July



June 30 ~ July 2, 2003
The Greenbrier –
White Sulpher Springs,
West Virginia

*Interdisciplinary Surgical
Treatment Planning and
Enhancing Outcomes Utilizing the
MBT™ System Arnett/McLaughlin
Treatment Analysis*
Dr. Richard McLaughlin and Dr. G. William Arnett

October



October 24 ~ October 25, 2003
Summit in New Orleans

Management of the Dentition
Dr. Richard McLaughlin
*Understanding the MBT™ System
for Orthodontic Treatment*
Dr. John McDonald
*Organizational Management of the
Orthodontic Practice ~ A Team Approach*
Ms. Lori Garland Parker

*Seating is limited, so register early
and secure a seat!*

**To register by phone,
call 1-800-852-1990 ext. 4649,
or contact your 3M Unitek representative.**

3M Unitek
• Orthodontic Products
2724 South Peck Road
Monrovia, CA 91016 USA

www.3MUnitek.com

Have technical questions?

3M Unitek Technical Hotline, (800) 265-1943
In Canada (800) 443-1661 ext. 4577

Worldwide (626) 574-4577;
(626) 574-4000 General Information

012-143 0304

3M Unitek

Products that make your life easier.